

Background

Quantitative evaluation of automatic fundus image segmentation methods requires a database with manually labeled gold standards.

Only a few public online evaluation databases are available. For example, the most common databases used for vessel segmentations [1, 2] contain low resolution images, which were taken 10 to 15 years ago.

State-of-the-Art segmentation methods require new gold standard images with high resolution for a proper evaluation.

Purpose

Our aim is to establish a database of high resolution fundus images with gold standards for most kinds of segmentation algorithms, and a website, where researchers can compare their segmentation methods.

Methods

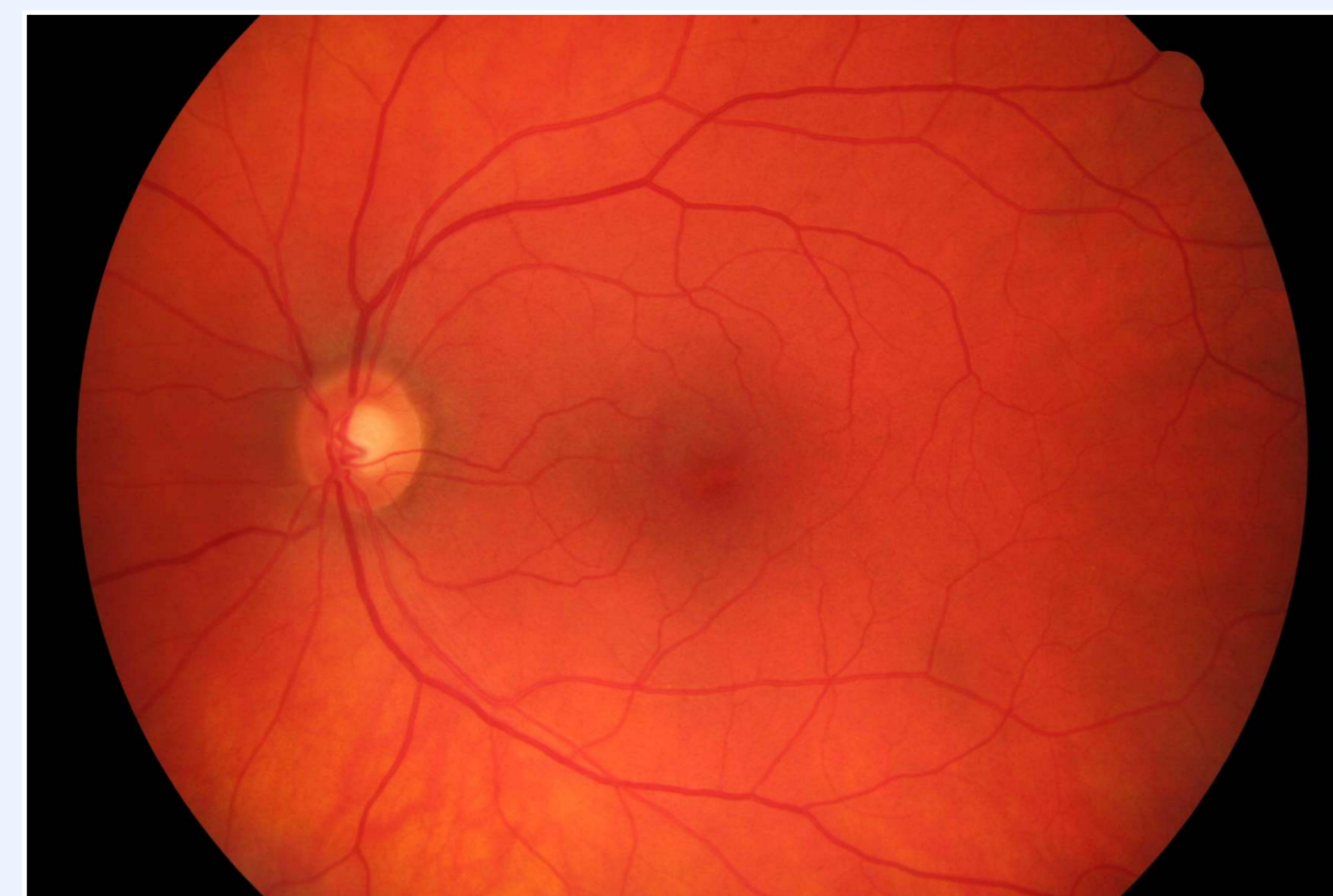The proposed database contains over 30 fundus images. The pictures are anonymous and show mainly healthy eyes and eyes with diabetic retinopathy. All of these images share the following properties:

- Taken by an expert using a CANON CF-60UVi camera
- Resolution of 3504x2336 pixels
- Manual labeling is done for vessel segmentation by experts in vessel segmentation
- Free to use for research purposes

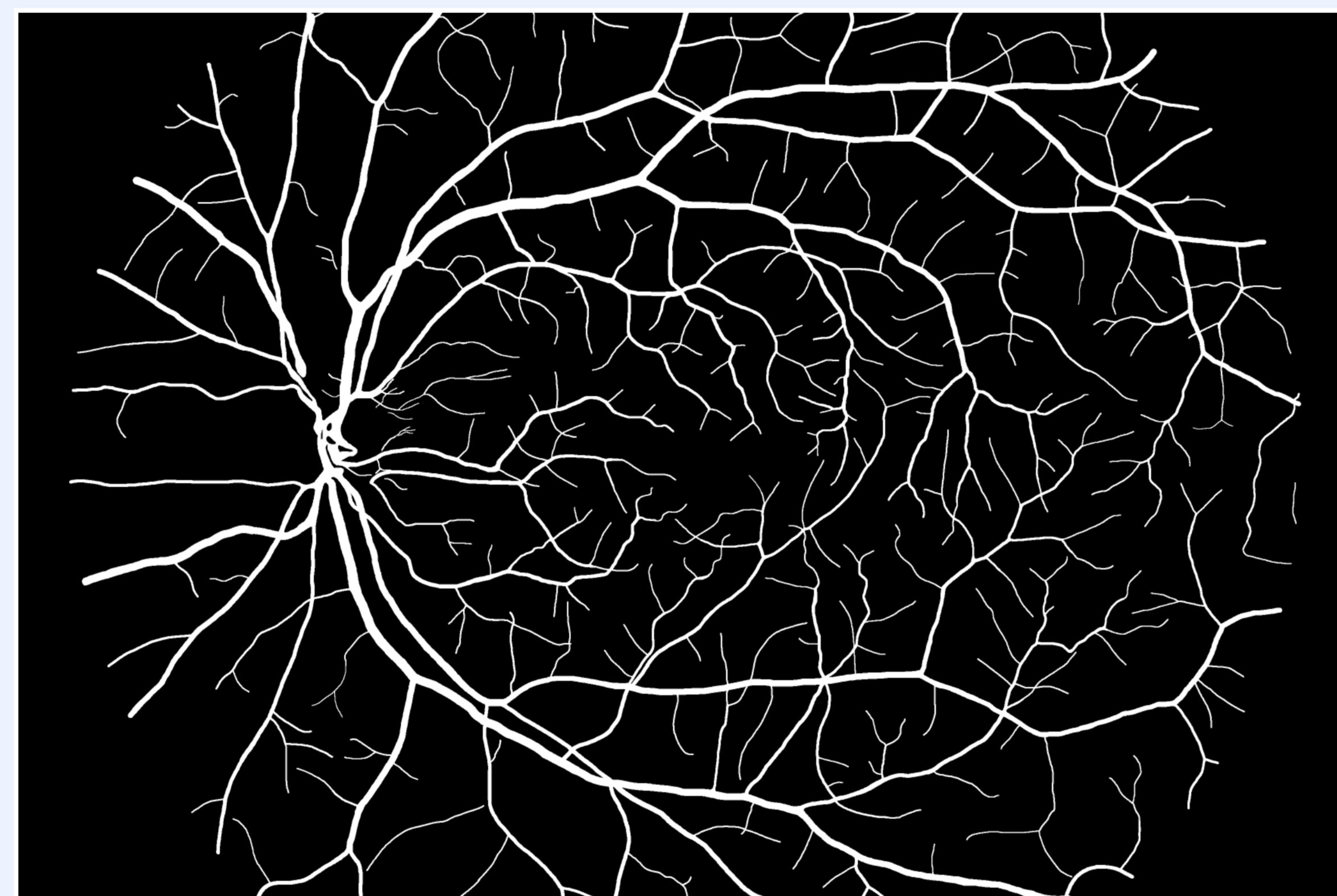
The database is available online:

www5.informatik.uni-erlangen.de/research/data/fundus-images

Figure 1 shows an example fundus image of the proposed database with the corresponding manual segmentation:



(a)



(b)

Figure 1: Example fundus image of the proposed database (a) and the manual segmentation of the vessels (b)

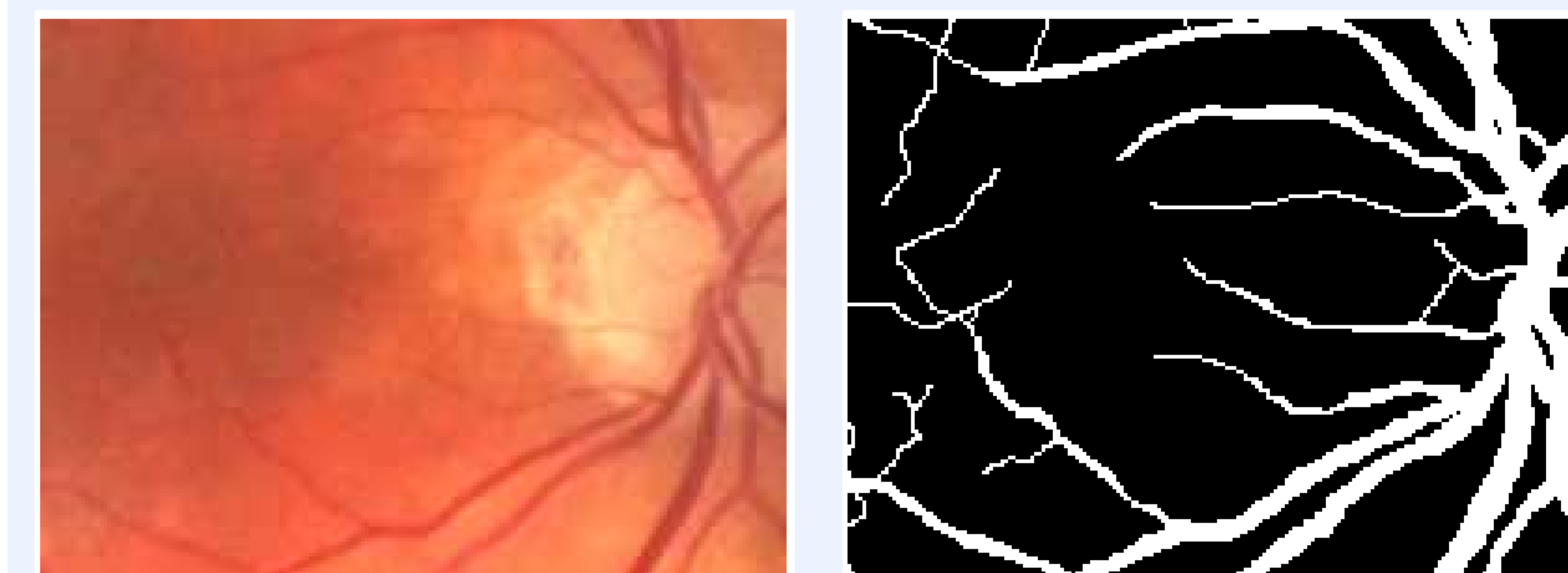
The website mentioned above will serve as a portal for the comparison of segmentation methods.

The authors want to support the evaluation and comparison of segmentation results by **establishing** not only **a public collection of manually segmented images**, but a list of methods which were already evaluated using the database.

Therefore, the authors encourage everyone to use the database and send back their results and a reference to a publication where the algorithm is described. **The collected results and comparisons will be available on the web page with the given references.**

Results

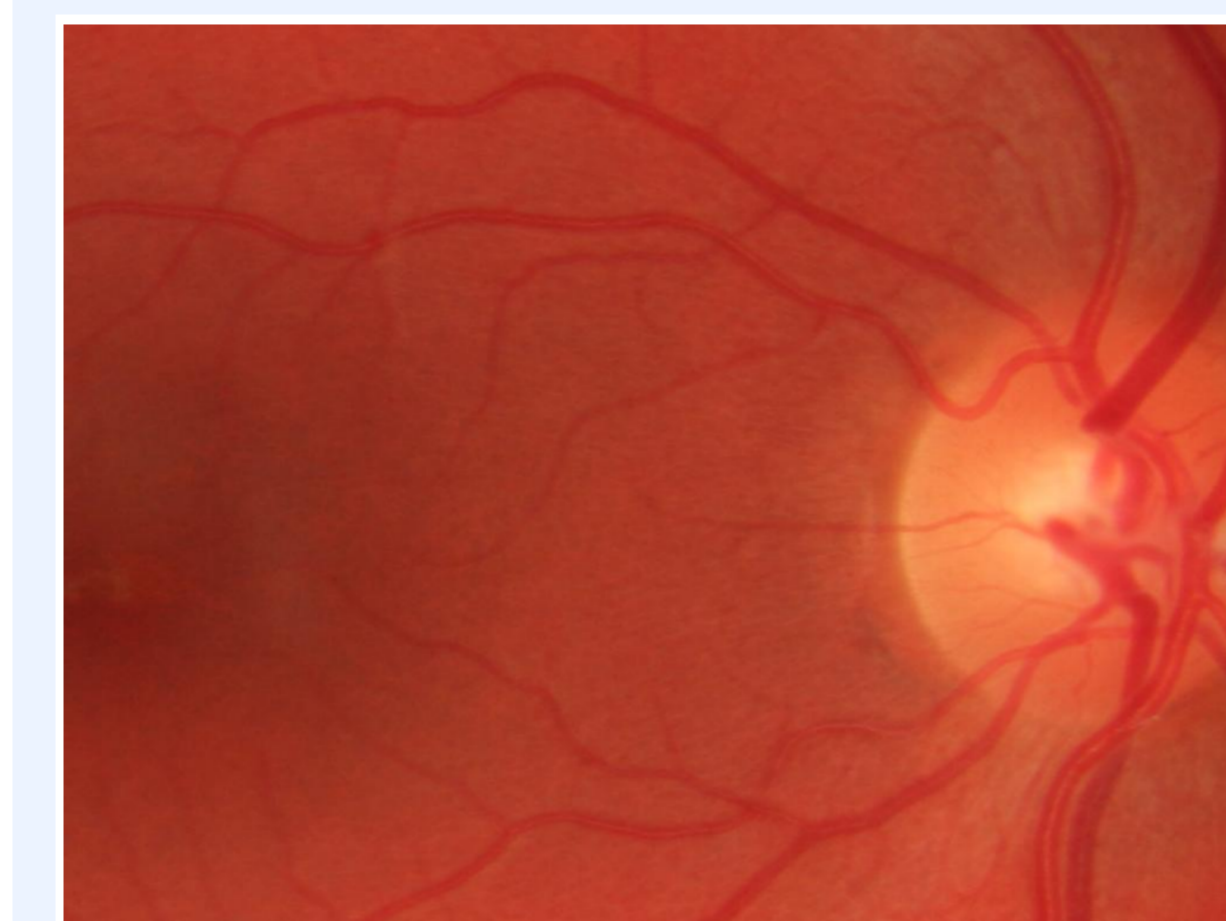We compared the existing databases and the proposed one. The following figure shows the region between the macula and the optic nerve head of an image from a standard public database and a similar region in one of the images in the proposed database.



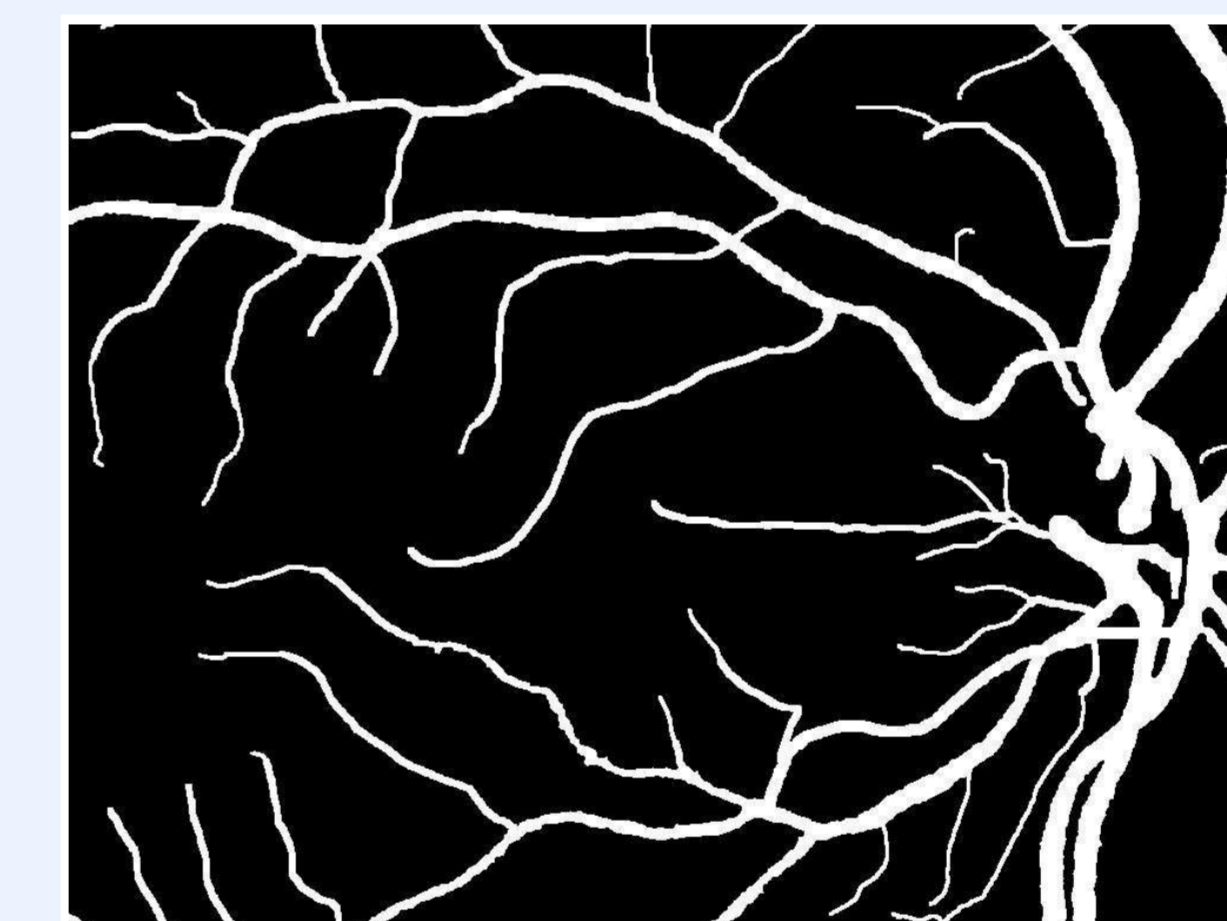
(a)



(b)



(c)



(d)

Figure 2: A subregion of an image from the DRIVE[2] database (a) and a similar region from the proposed database (c), and their respective manual segmentation results (b,d)

Vessel segmentation methods developed by the first and second authors were tested using the first available images of the proposed database. **The following table shows the preliminary results of the evaluations.** This measurements are already available on the web page, but may be refined later.

| Author | Sensitivity | specificity | Accuracy |
|------------------------------|--------------|--------------|--------------|
| Budai <i>et al.</i> [3] | 70.99 ± 4.00 | 97.45 ± 0.44 | 94.81 ± 0.60 |
| Odstrcilik <i>et al.</i> [4] | 81.65 ± 4.04 | 96.09 ± 0.62 | 94.48 ± 0.75 |
| Blank result | 0.00 ± 0.00 | 90.61 ± 0.93 | 90.61 ± 0.93 |

The following table shows the same measurements using the public DRIVE[2] database, which is often used to evaluate segmentation methods, but contains only lower resolution images.

| Author | Sensitivity | specificity | Accuracy |
|------------------------------|--------------|--------------|--------------|
| Budai <i>et al.</i> [3] | 74.00 ± 0.04 | 97.30 ± 0.04 | 95.20 ± 0.00 |
| Odstrcilik <i>et al.</i> [4] | 70.60 ± 5.06 | 96.93 ± 0.64 | 95.19 ± 0.98 |

Conclusion

We provide a **high resolution fundus image database for the evaluation of segmentation methods.** We are establishing a webpage where **authors can compare their results** to other authors.

Outlook

- Manual labeling for differentiation of arteries and veins
- Manual labeling for segmentation of optic disk/cup regions
- gold standard for Macula region localization
- Images of patients with Glaucoma
- Images of patients with Diabetic Retinopathy

Support

The authors gratefully acknowledge funding of the Erlangen Graduate School in Advanced Optical Technologies (SAOT) and the International Max Planck Research School for Optics and Imaging

Commercial Relationship

Attila Budai, None; Jan Odstrcilik, None; Radim Kolar, None; Joachim Hornegger, None; Jiri Jan, None; Tomas Kubena, None; Georg Michelson, None

References

- [1] B. McCormick *et al.*: STARE = Structured Analysis of the Retina: Image processing of TV fundus image, in: at USA-Japan Workshop on Image Processing, Jet Propulsion Laboratory, Pasadena, CA, October 31, 1975.
- [2] J.J. Staal *et al.*: Ridge based vessel segmentation in color images of the retina, IEEE Transactions on Medical Imaging, 2004, vol. 23, pp. 501-509.
- [3] A. Budai *et al.*: Multiscale Approach for Blood Vessel Segmentation on Retinal Fundus Images. In Invest Ophthalmol Vis Sci 2009;50: E-Abstract 325, 2009.
- [4] J. Odstrcilik *et al.*: Improvement of vessel segmentation by matched filtering in colour retinal images. In IFMBE Proceedings of World Congress on Medical Physics and Biomedical Engineering, pages 327 - 330, 2009.