

The American Journal of Sports Medicine

<http://ajs.sagepub.com/>

Chronic Achilles Tendinopathy

Wolf Petersen, Robert Welp and Dieter Rosenbaum

Am J Sports Med 2007 35: 1659 originally published online June 14, 2007

DOI: 10.1177/0363546507303558

The online version of this article can be found at:

<http://ajs.sagepub.com/content/35/10/1659>

Published by:



<http://www.sagepublications.com>

On behalf of:



[American Orthopaedic Society for Sports Medicine](http://www.aossm.org)

Additional services and information for *The American Journal of Sports Medicine* can be found at:

Email Alerts: <http://ajs.sagepub.com/cgi/alerts>

Subscriptions: <http://ajs.sagepub.com/subscriptions>

Reprints: <http://www.sagepub.com/journalsReprints.nav>

Permissions: <http://www.sagepub.com/journalsPermissions.nav>

Chronic Achilles Tendinopathy

A Prospective Randomized Study Comparing the Therapeutic Effect of Eccentric Training, the AirHeel Brace, and a Combination of Both

Wolf Petersen,^{*†} MD, Robert Welp,[‡] MS, and Dieter Rosenbaum,[‡] PhD
From the [†]Department of Trauma, Hand, and Reconstructive Surgery and the [‡]Movement Analysis Lab, Orthopaedic Department, University Hospital Muenster, Muenster, Germany

Background: Previous studies have shown that eccentric training has a positive effect on chronic Achilles tendinopathy. A new strategy for the treatment of chronic Achilles tendinopathy is the AirHeel brace.

Hypothesis: AirHeel brace treatment improves the clinical outcome of patients with chronic Achilles tendinopathy. The combination of the AirHeel brace and an eccentric training program has a synergistic effect.

Study Design: Randomized controlled clinical trial; Level of evidence, 1.

Methods: One hundred patients were randomly assigned to 1 of 3 treatment groups: (1) eccentric training, (2) AirHeel brace, and (3) combination of eccentric training and AirHeel brace. Patients were evaluated at 6, 12, and 54 weeks after the beginning of the treatment protocol with ultrasonography, visual analog scale (VAS) for pain, American Orthopaedic Foot and Ankle Society (AOFAS) ankle score, and Short Form-36 (SF-36).

Results: The VAS score for pain, AOFAS score, and SF-36 improved significantly in all 3 groups at all 3 follow-up examinations. At the 3 time points (6 weeks, 12 weeks, and 54 weeks) of follow-up, there was no significant difference between all 3 treatment groups. In all 3 groups, there was no significant difference in tendon thickness after treatment.

Conclusions: The AirHeel brace is as effective as eccentric training in the treatment of chronic Achilles tendinopathy. There is no synergistic effect when both treatment strategies are combined.

Clinical Relevance: The AirHeel brace is an alternative treatment option for chronic Achilles tendinopathy.

Keywords: Achilles; tendinopathy; AirHeel brace; eccentric training; ultrasonography

Chronic Achilles tendon pain, manifested as a localized painful thickening of the tendon, is relatively common among middle-aged recreational athletes.^{1-3,5,9,11,15,21} Gradual onset of pain in the Achilles tendon with structural changes in the midportion of the tendon (2-8 cm above the calcaneal insertion) is called tendinopathy and is generally considered to be a difficult condition to treat.^{2,10,11,22,24,28}

*Address correspondence to Wolf Petersen, MD, Department of Trauma-, Hand-, and Reconstructive Surgery, Westfalian Wilhelms University of Muenster, Waldeyerstr. 1, D-48149 Muenster, Germany (e-mail: wolf.petersen@ukmuenster.de).

One or more of the authors has declared a potential conflict of interest: All 3 authors received funds for research from Aircast Europe.

The American Journal of Sports Medicine, Vol. 35, No. 10
DOI: 10.1177/0363546507303558
© 2007 American Orthopaedic Society for Sports Medicine

Several studies have demonstrated that treatment by heavy-load eccentric calf muscle training leads to good clinical results, with decreased pain and full recovery to previous activity level.^{2,7,8,17,18,23,28-30} Therefore, this treatment strategy has to be considered the standard for the treatment of chronic tendinopathy of the Achilles tendon. However, our clinical experience with eccentric training has shown that some patients discontinue this treatment because of the experience of pain during exercise.

Conservative treatment options other than eccentric training for chronic Achilles tendon pain have previously been less encouraging.⁴ In one literature review, the authors stated that many common treatments such as rest, strength and flexibility exercises, anti-inflammatory agents, or corticosteroids do not alter the natural course of this disease.⁴ These inconclusive results are explained with the multifactorial origin of Achilles tendinopathy so

TABLE 1
Data on 100 Patients With Chronic Achilles Tendon Pain^a

	All (N = 100)		Group 1 Eccentric Training (n = 37)		Group 2 AirHeel (n = 35)		Group 3 Combination (n = 28)		P Value
	Mean	SD	Mean	SD	Mean	SD	Mean	SD	
Age (y)	42.5	11.07	42.1	11	42.6	10.7	43	12	n.s.
Height (cm)	177.2	8.89	176.4	9.3	177.9	8.9	177.5	8.6	n.s.
Weight [kg]	79.7	14.25	79.4	17.1	82.3	13.4	76.9	10.7	n.s.
BMI (kg/m ²)	25.3	3.97	25.4	4.8	26	3.8	24.4	2.9	n.s.
Duration of symptoms (mo)	7.4	2.3	7.1	2.6	7.3	2.5	7.0	2.3	
Male/female	60/40		23/14		20/15		17/11		
Active in sports	92		34		32		26		

^aSD, standard deviation; n.s., not significant; BMI, body mass index.

that one single treatment appears insufficient. Very few prospective randomized controlled trials exist to assist in choosing the best evidence-based treatment.⁴

Chronic Achilles tendinopathy is often associated with paratendinitis.^{13,19,21,24} Local massage is regarded as an important technique to loosen adhesions in paratendinopathy and to remove metabolites and other waste products via the venous plexus of the paratenon, and might have a positive effect on the course of chronic Achilles tendinopathy.¹⁶

The AirHeel brace (Aircast, Vista, Calif) is specifically designed to treat Achilles tendinopathy. The manufacturer claims that the 2 interconnected air cells located under the heel and above the calcaneus apply pulsating compression with every step to help reduce swelling and discomfort, and enhance circulation by a local massage effect, but these effects have not been proven with scientific studies.

The purpose of this prospective randomized study was to evaluate 3 different treatment protocols for chronic midportion tendinopathy of the Achilles tendon: (1) eccentric training, (2) the AirHeel brace, and (3) a combination of eccentric training and the AirHeel brace.

Our first hypothesis was that the AirHeel brace improves symptoms of chronic noninsertional tendinopathy. The second hypothesis was that the combination of eccentric training with the AirHeel brace has a synergistic effect.

MATERIAL AND METHODS

One hundred patients were included in the study and randomly assigned to one of the 3 different treatment groups (Table 1): group 1, eccentric training (37 patients); group 2, AirHeel brace (35 patients); and group 3, combination of the AirHeel brace and eccentric training (28 patients).

The patients were recruited by announcing the study in local newspapers. Randomization for assigning the subjects to a treatment group was achieved with selecting random numbers between 1 and 3 in Microsoft Excel (Microsoft Corp, Redmond, Wash).

All of these patients had been suffering from a gradually evolving painful condition in the Achilles tendon located at the midportion for at least 3 months. Most of the patients

were recreational athletes involved in activities such as jogging or running (29%), walking (15%), or other sports activities (33%).

In all cases, the diagnosis was based on clinical examination performed by the same investigator (R.W.), showing a painful thickening of the Achilles tendon located at a level of 2 to 6 cm above the tendon insertion. In all tendons, the diagnosis was confirmed by ultrasonography, in which the tendon changes were described as a local thickening of the tendon, irregular tendon structure with hypoechoic areas, and irregular fiber orientation.

In all cases, the condition caused pain during tendon loading that limited the desired activity level. Most patients (87 of 100) had previously been advised to treat the problem by resting the affected leg. A majority of the symptomatic tendons had been treated with other treatment regimens (nonsteroidal anti-inflammatory drugs, 78; local cortisone injection, 3; physiotherapy, 45; or orthotic treatment, 23) without satisfactory effect on the Achilles tendon pain. Patients with previous surgery or tendon rupture were excluded from this study.

At the initial visit, a clinical examination with assessment of height, body weight, and assessment of local tenderness was performed in every patient. The amount of pain during rest and activity was evaluated by the patients on a 10-cm-long visual analog scale (VAS). On the VAS, the amount of pain is recorded from 0 to 10 cm, where no pain is recorded as 0 and severe pain is recorded as 10. The joggers registered the amount of pain during jogging, runners during running, and walkers during walking (ie, registration depended on the patient's type of activity). Function of the hindfoot region was assessed with the American Orthopaedic Foot and Ankle Society (AOFAS) hindfoot scale.¹⁴ Every patient completed the Short Form-36 (SF-36). Ultrasound examination was performed to evaluate thickening of the tendon in its midportion (2-6 cm above the insertion) and the presence of paratendinitis. The tendon diameter was evaluated on longitudinal cross-sections. Other findings such as hypoechogenic structures, nodules, etc were also noted. All patients with pain at the insertion of the tendon (insertional tendinitis) or Haglund deformity were excluded from the study.



Figure 1. Eccentric training. From an upright body position and standing with the whole body weight on the forefoot, with the ankle joint in plantar flexion (A), the calf muscles were loaded by lowering the heel (B). Two types of exercises were used. The calf muscle was eccentrically loaded both with the knee straight (C) and, to maximize the activation of the soleus muscle, with the knee slightly bent.

Eccentric Training Model

All patients in this intervention group were instructed on how to perform the eccentric training by the same investigator (R.W.). They were given practice instruction and a written manual on how to progress. The correct execution of the exercises was confirmed after 6 weeks. The training protocol was adopted from previous studies.² The patients were instructed to perform the eccentric exercises 3 times daily, 7 days per week, for 12 weeks. They were also advised to use stable shoes when performing the exercises.

In the beginning, the loading consisted of the body weight. From an upright body position and standing with the whole body weight on the forefoot, with the ankle joint in plantar flexion (Figure 1A), the calf muscles were loaded by lowering the heel (Figure 1B). Two types of exercises were used. The calf muscle was eccentrically loaded both with the knee straight (Figure 1C) and, to maximize the activation of the soleus muscle, with the knee slightly bent. The calf muscles were only loaded eccentrically; no following concentric contraction was performed, as the patients were instructed to use the noninjured leg and/or the arms to return to the starting position.

Each of the 2 exercises included 3 sets of 15 repetitions. The patients were told that muscle soreness during the first 1 to 2 weeks of training was to be expected and that the exercises were potentially painful, but to stop if the pain became disabling. When the patients could perform the eccentric loading without experiencing any minor pain or discomfort, they were instructed to increase the load on the tendon by using a backpack increasingly loaded with weights to reach a higher level of training. Thus, the eccentric loading of the calf muscles was gradually increased.

During the 12-week training regimen, jogging, walking, and bicycling were allowed if it could be performed with only mild discomfort or pain.

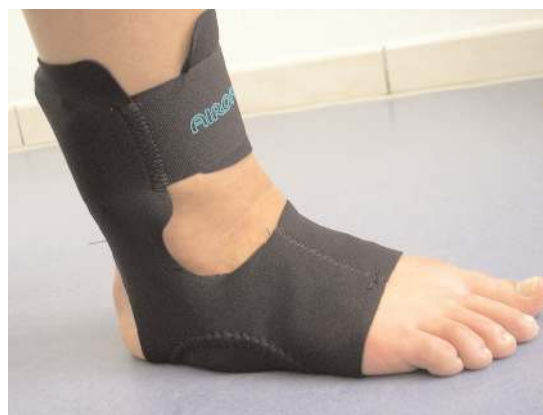

Figure 2. The AirHeel brace.

AirHeel Treatment

The AirHeel is a specifically designed brace for the treatment of Achilles tendinopathy (Figure 2). Patients were instructed to wear the AirHeel during the daytime.

Evaluation

The evaluation of the efficacy of the treatment regimen was performed after 6 and 12 weeks of the intervention. At each follow-up, the outcome was assessed with the VAS for pain at rest, during gait, and during sports activities; the AOFAS hindfoot scale; the SF-36; and ultrasound examination. To avoid bias, the evaluation of the VAS and the SF-36 was done by the patient alone. All patients were questioned for possible adverse effects of the treatments (eg, tendon rupture, discomfort, severe pain).

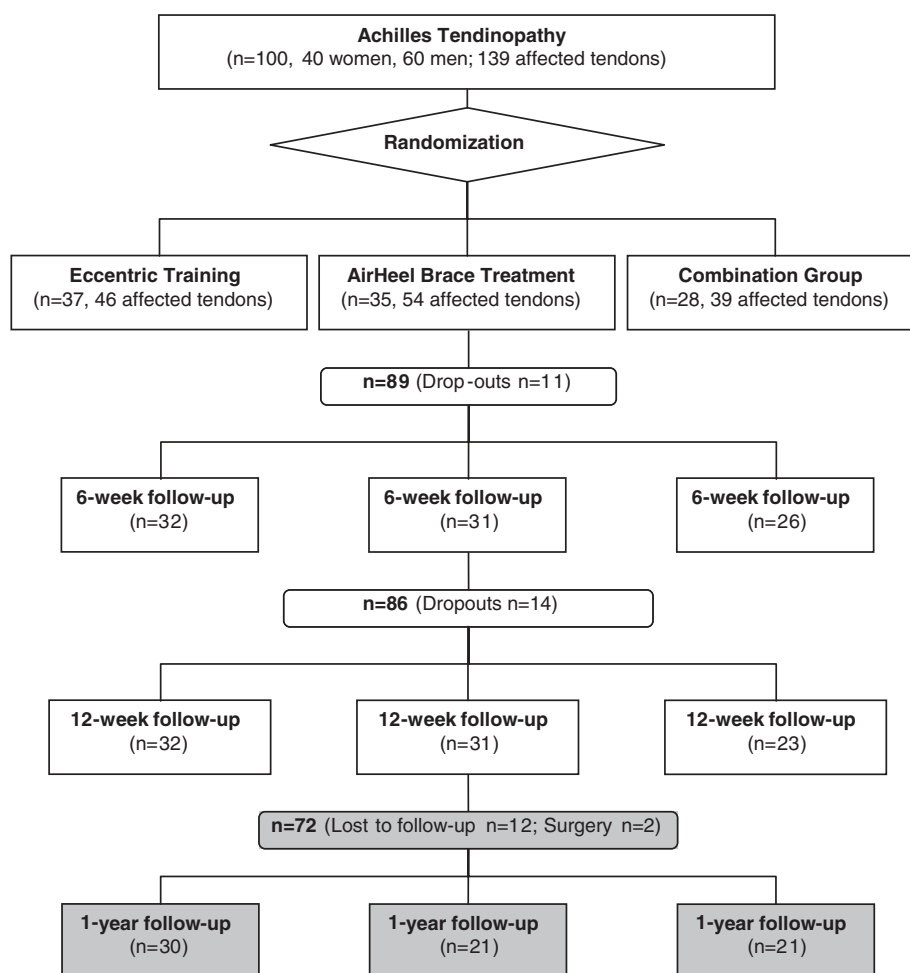


Figure 3. This flowchart shows the fate of all patients entering the study at the 3 time points.

For a 1-year follow-up, patients were asked to fill out the questionnaires for the AOFAS, report the pain on the VAS, and to report whether they reached their preinjury sports level.

Ethics

The experimental protocol for this study was approved by the Ethical Committee of our University. All patients gave their consent to participate in this treatment model.

Statistical Evaluation

Commercial software (StatView 5.0, SAS Institute, Cary, NC) was used for all statistical calculations. A repeated-measures analysis (3 groups by 4 measurements) was performed. The results are expressed as mean \pm standard deviation (SD) throughout this article. A P value $< .05$ was considered significant.

RESULTS

Anthropometric Data of the 3 Treatment Groups

The anthropometric data of the patients involved in the present study show that there were no significant differences

in age, duration of symptoms, gender, height, weight, and body mass index between the 3 treatment groups (Table 1).

The total dropout rate during the 12-week treatment period was 14% and did not differ between the 3 treatment groups. Some of the dropout patients discontinued the eccentric training because of severe pain experienced during the exercises. The main reason for dropout in the AirHeel group was discomfort due to poor fitting of the brace.

At the 1-year follow-up, two patients (1 in the AirHeel group, 1 in the eccentric training group) had undergone surgery. Twelve patients were lost to follow-up. Figure 3 shows the fate of all patients entering the study.

American Orthopaedic Foot and Ankle Society (AOFAS) Score

The AOFAS score improved significantly during the course of the study, from 77 points to 85 points after 6 weeks, to 89 points after 12 weeks, and to 85 points after 54 weeks of treatment (Figure 4) without any significant differences between the 3 different treatment groups. At the 1-year follow-up, the AOFAS score was still improved by 10% in the eccentric training group and in the brace group, and by 12% in the combination group as compared with the pretreatment situation. These differences were significant ($P < .0001$).

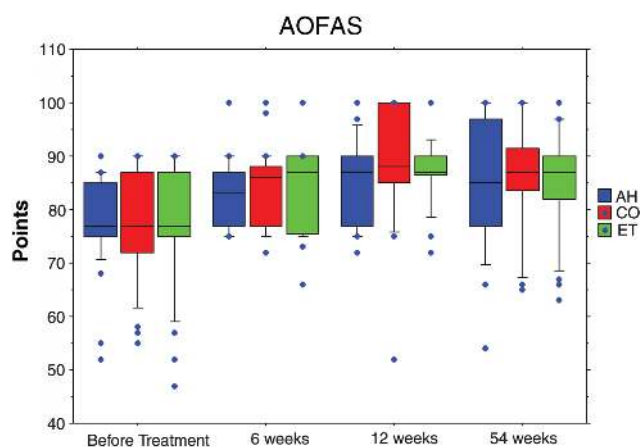


Figure 4. Changes in the American Foot and Ankle Society (AOFAS) score of all subjects as well as 3 groups separately. The dots above the boxes represent observations above the 90th percentile. The boxes show the median (middle line), 75th percentile (top line), and 25th percentile (bottom line). The whiskers above the box show the 90th percentile and those below the box, the 10th percentile. The dots below the box represent observations below the 10th percentile. AH, AirHeel group; CO, combination group; ET, eccentric training group.

Pain

Pain during activities of daily living assessed with a VAS (where 0 cm = no pain and 10 cm = severe pain) improved significantly in all 3 treatment groups (Figure 5). In group 1 (eccentric training) and group 3 (combination), pain was reduced 20% and 22% after 6 weeks and 60% and 56% after 12 weeks, respectively. In group 2 (AirHeel), pain was reduced by 41% after 6 weeks with no further decrease after 12 weeks (35%). At the 1-year follow-up, pain was still reduced by 30% in the eccentric training group, by 27% in the brace group, and by 53% in the combination group as compared with the pretreatment situation. These differences were significant ($P < .0001$).

Pain during walking was higher than pain during activities of daily living, but there was also a significant improvement of pain during walking assessed with the VAS in all 3 study groups (Figure 6). In group 1, there was a 25% decrease of pain after 6 weeks and 71% decrease after 12 weeks. In group 2 and in group 3, there was a pain reduction of 43% and 36%, respectively, after 6 weeks but there was no significant further pain reduction after 12 weeks (group 2, 50%; group 3, 56%). At the 1-year follow-up, pain during walking was still reduced by 45% in the eccentric training group, by 46% in the brace group, and by 64% in the combination group as compared with the pretreatment situation. These differences were significant ($P < .0001$).

The highest pain level (overall 5.7) was experienced during sports activities. In each treatment group, the pain level decreased significantly at 6 and 12 weeks (Figure 7). At each time point, there was no significant difference between the 3 treatment groups. At the 1-year follow-up, pain was still reduced by 51% in the eccentric training group, by 47% in the brace group, and by 74% in

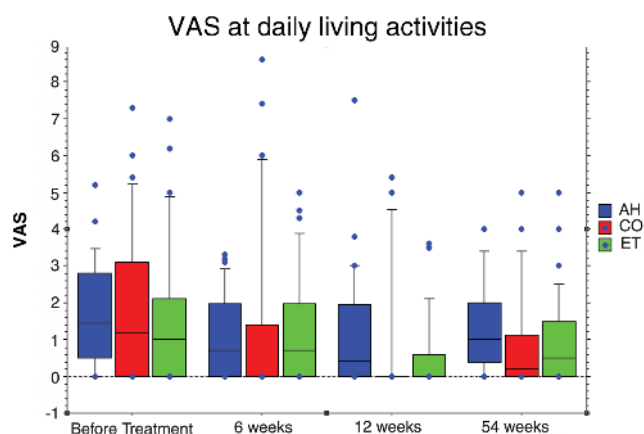


Figure 5. Changes of the pain situation in normal activities of daily living, measured on a visual analog scale (VAS). The dots above the boxes represent observations above the 90th percentile. The boxes show the median (middle line), 75th percentile (top line), and 25th percentile (bottom line). The whiskers above the box show the 90th percentile and those below the box, the 10th percentile. The dots below the box represent observations below the 10th percentile. AH, AirHeel group; CO, combination group; ET, eccentric training group.

the combination group as compared with the pretreatment situation. These differences were significant ($P < .0001$).

In all pain categories, the eccentric training group and the brace group had lost some of the benefit seen after the 12-week treatment period whereas the combination group showed a further improvement. However, no significant group differences were seen in any of these parameters.

Ultrasonography

At the initial examination, the sagittal tendon diameter was significantly greater than the diameter of the healthy contralateral side. However, during the course of the study, there was no change in the tendon diameter in any of the 3 treatment groups.

Short Form-36

The SF-36 was used for quality of life assessment at time point 0, and after 6 and 12 weeks of treatment (Table 2). Only 2 of the 8 different categories improved significantly during the course of the study—function and pain. Function improved by about 13% in group 1 and in group 2. In group 3, function improved by about 17%. Pain also improved significantly, by about 13% in group 1 and group 2. In group 3, pain improved by 19%. There was no significant difference between the 3 treatment groups.

Return to Sports

Return to preinjury sports level was evaluated after 54 weeks. Ninety percent of patients reached their preinjury activity level. There was no statistical significant difference between the groups.

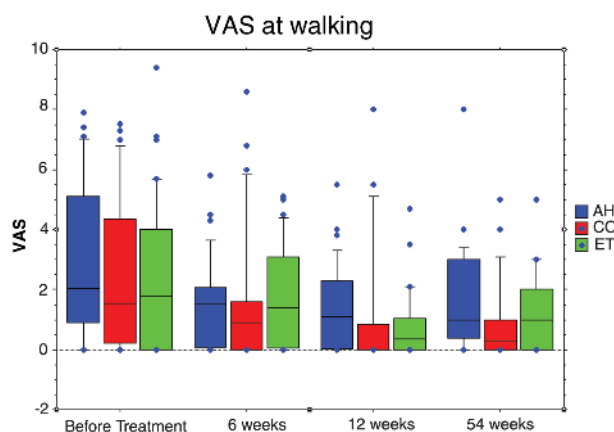


Figure 6. Changes of the pain situation during gait activities, measured on a visual analog scale (VAS). The dots above the boxes represent observations above the 90th percentile. The boxes show the median (middle line), 75th percentile (top line), and 25th percentile (bottom line). The whiskers above the box show the 90th percentile and those below the box, the 10th percentile. The dots below the box represent observations below the 10th percentile. AH, AirHeel group; CO, combination group; ET, eccentric training group.

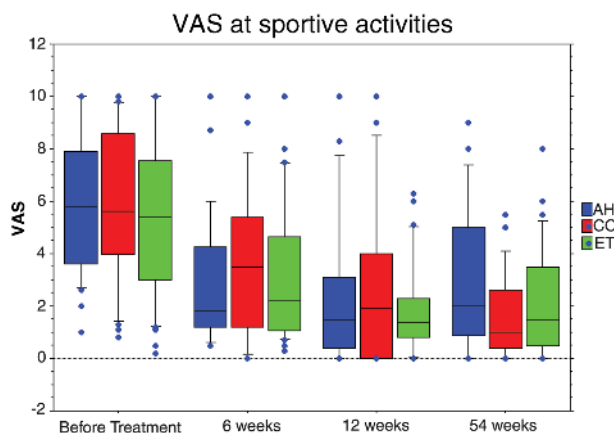


Figure 7. Changes of the pain situation during sports activities, measured on a visual analog scale (VAS). The dots above the boxes represent observations above the 90th percentile. The boxes show the median (middle line), 75th percentile (top line), and 25th percentile (bottom line). The whiskers above the box show the 90th percentile and those below the box, the 10th percentile. The dots below the box represent observations below the 10th percentile. AH, AirHeel group; CO, combination group; ET, eccentric training group.

DISCUSSION

Although the amount of improvement was very modest, the results of this study support our first hypothesis. A 12-week treatment with the AirHeel brace improved symptoms of patients with chronic midportion tendinopathy of

the Achilles tendon. The second hypothesis of this study was only partially supported by the results of the present study. Only the SF-36 showed a synergistic effect of both treatments. Function improved by about 13% in the eccentric training group and in the AirHeel brace group. Function improved by about 17% when both treatments were combined. Pain also improved significantly, by about 13% in the eccentric training group and in the AirHeel brace group. Pain improved by about 19% in the combination group.

It is difficult to compare outcome between studies because different measures of outcome are often used.⁴ Although patients' perception of general health is considered to be increasingly important, only a few studies on Achilles tendinopathy have used this as a measure of outcome.^{6,20} The SF-36 is one of the most widely used instruments for addressing patient self-assessment.³² Clinical experience of patients with intra-articular calcaneus fractures has shown that limitations in many fields of daily life are to be expected. In a study about the outcome after surgical treatment of calcaneal fractures, Westphal et al³³ showed that the SF-36 detects more limitations in general health status than other classic instruments. In this context, the SF-36 seems to be an ideal tool for measuring outcome and should be used in future studies. In our study, only 2 of the 9 SF-36 item scores improved significantly—pain and functional status. The amount of improvement in these 2 categories was quite low. It is difficult to judge if this moderate increase represents a “practical” improvement from the patient's point of view.

The SF-36 is not a disease-specific instrument; therefore, it is not capable of detecting specific symptoms and limitations in patients with Achilles tendinitis. Another widely used instrument for the assessment of hindfoot disorders is the AOFAS score.¹⁴ With this score, the eccentric training group and the AirHeel group improved but there was no synergistic effect when both treatments were combined. The same result was obtained with the VAS assessment of pain.

Although we could not replicate the very good results after eccentric training found in other studies, the results of this study support findings of previous studies regarding the effect of the eccentric training.^{2,7,8,18,28-30} Several previous studies could demonstrate that eccentric exercises improve pain and function in cases of chronic midportion tendinopathy of the Achilles tendon. The concept of eccentric training as treatment for chronic Achilles tendinopathy was introduced by Stanish et al.³⁰ The exact background of the good clinical results achieved with this method has long been unknown. It was believed that eccentric loading of the tendon enhances collagen fibril alignment with increased tensile strength, encourages fibroblast activity, and prevents adhesions between the healing tendon and adjacent tissue.⁷

Recent studies have shown that an effect on neovascularization could be responsible for the good result with eccentric training in chronic midportion Achilles tendinopathy.^{8,22} In a clinical study, Öhberg et al²³ showed that in the majority of tendons with a good result after eccentric training, the neovessels that had been demonstrated in all tendons

TABLE 2
Short Form-36 Scores^a

All	0 Weeks		6 Weeks		12 Weeks		P Value
	Mean	SD	Mean	SD	Mean	SD	
Physical functioning	75.0	21.6	84.3	17.3	88.2	14.1	< .0001
Physical role	81.8	33.8	89.2	26.2	91.4	23.4	n.s.
Bodily pain	57.8	22.6	67.1	18.9	72.8	20.0	< .0001
General health	71.1	16.9	71.7	18.1	72.2	18.2	n.s.
Vitality	62.8	15.3	62.9	17.6	65.8	15.5	n.s.
Social functioning	88.3	16.9	90.7	18.0	92.8	12.5	n.s.
Emotional role	93.3	23.2	92.2	24.5	94.0	19.5	n.s.
Mental health	76.1	14.8	75.9	14.6	76.7	14.4	n.s.
Group 1: Eccentric Training							
Physical functioning	76.1	21.6	85.0	16.4	87.7	12.2	.0035
Physical role	79.7	35.8	93.5	20.4	88.0	26.3	n.s.
Bodily pain	56.5	25.8	68.9	18.0	69.9	22.3	.0156
General health	69.2	16.5	74.5	15.7	74.4	14.6	n.s.
Vitality	61.6	14.3	65.5	13.3	65.9	15.3	n.s.
Social functioning	89.9	18.8	89.5	20.2	91.9	13.9	n.s.
Emotional role	92.8	23.7	87.1	30.6	94.6	17.4	n.s.
Mental health	75.4	14.6	76.4	13.5	75.7	12.6	n.s.
Group 2: AirHeel							
Physical functioning	76.3	19.8	84.2	14.4	88.0	13.0	.0007
Physical role	81.4	33.4	86.7	25.2	95.0	13.8	n.s.
Bodily pain	58.4	22.2	65.2	20.7	72.0	17.9	.0053
General health	73.9	15.5	70.4	17.8	67.9	17.8	n.s.
Vitality	64.4	14.4	64.8	19.3	65.3	16.0	n.s.
Social functioning	87.5	13.2	91.8	17.4	93.1	11.4	n.s.
Emotional role	94.3	23.6	97.7	8.6	95.6	11.5	n.s.
Mental health	76.3	16.4	74.9	15.8	78.0	15.2	n.s.
Group 3: Combination							
Physical functioning	71.8	24.0	83.6	21.8	89.3	17.9	< .0001
Physical role	85.2	32.7	87.0	33.2	91.3	28.8	n.s.
Bodily pain	58.8	19.1	67.0	18.2	77.7	19.3	.0002
General health	70.1	19.0	69.7	21.2	74.7	22.5	n.s.
Vitality	62.1	17.9	57.6	19.6	66.3	15.8	n.s.
Social functioning	87.0	18.8	91.0	16.3	93.5	12.4	n.s.
Emotional role	92.9	22.9	92.0	27.7	91.3	28.8	n.s.
Mental health	76.7	13.5	76.5	15.0	76.3	16.2	n.s.

^aSD, standard deviation; n.s., not significant.

before treatment had disappeared at follow-up. In the 5 tendons with a poor result of treatment, there was remaining neovascularization.²³ Several studies have shown that tendons with chronic tendinopathy had significantly more blood vessels than normal tendons.^{23,25-27} The occurrence of neovascularization in the area with tendon changes, demonstrated with color Doppler examination simultaneously with ultrasonography, has been shown to possibly be correlated with pain in chronic midportion Achilles tendinopathy.²³ From another study on biopsies from Achilles tendinopathy tissue, we know that there are nerve structures in the proximity of the vascular wall¹; consequently, the area with neovascularization should be considered as an area with neovessels and accompanying

nerves. Alfredson et al³ used microdialysis and could show that concentrations of the neurotransmitter glutamate were significantly higher in tendons with chronic painful tendinopathy compared with pain-free (normal) Achilles tendons. In recent years, the importance of glutamate as a mediator of pain in the central nervous system has been emphasized.

In contrast to eccentric exercises, the explanation for the effect of the AirHeel brace demonstrated in this study is largely unknown. We speculate that the cyclic massage effect of this brace supports transport of metabolites such as glutamate or lactate via the venous plexus of the inflamed paratenon. A second explanation could be that the brace loosens adhesions built between the tendon,

paratenon, and the surrounding tissue. Further experimental studies are needed to evaluate the cause of the positive effect of the AirHeel brace on chronic Achilles tendinopathy as documented in this prospective randomized controlled trial. To our knowledge, there are no clinical studies about the AirHeel brace for chronic Achilles tendinopathy in the literature. Kavros et al¹² evaluated the efficacy of the AirHeel brace in the treatment of plantar fasciitis. In this study, the AirHeel group demonstrated significant improvement in pain.¹²

Poor methodology is one suggested reason for the weak evidence for treatment of tendinopathy.⁴ Therefore, care was taken that the methodologic suggestions proposed by Tallon et al³¹ were met in the present study. The complete study design was approved by the Ethical Committee of the medical faculty of our University as a prospective randomized controlled trial. Because placebo treatment was regarded as unethical, we chose the well-established eccentric training as a control group. A power analysis revealed that a minimum of 30 patients were needed in each group to detect a medium effect of the treatment modality. The treatment period was documented in detail for every patient to control for treatment adherence and compliance. The outcome assessments (AOFAS score, SF-36, VAS for pain) were in a written form with minimal investigator assistance. Because the literature provides no outcome instruments that have been validated for Achilles tendinopathy, we decided to use as many different outcome instruments as possible. All outcome instruments were used in previous studies about Achilles tendon or hindfoot disorders. Ultrasonography was performed to confirm the diagnosis of midportion tendinopathy and to diagnose associated paratenonitis. However, thickening of the tendon and structural changes were not inclusion criteria. All patients with pain from the insertion of the tendon were excluded from the study because previous studies have shown that pain at this location has a different origin (Haglund deformity, insertional tendinopathy) and does not respond well to eccentric exercises.²

Gray scale ultrasonography is commonly used to investigate Achilles tendon injuries and has been shown to be a reliable and cost-effective method of identifying abnormalities such as increased tendon thickness, hypoechoic areas, and irregular structure. Therefore, we decided to use ultrasonography to study tendon thickness and tendon structure before and after treatment with eccentric training. None of the treatment strategies tested in the present study could influence these structural changes. The short follow-up period for the ultrasound examination might be an explanation for this finding. Fahlström et al⁸ could show that tendon width had decreased significantly 3.8 years after eccentric calf muscle training. Furthermore, before treatment all patients had hypoechoic areas and an irregular tendon structure, but at follow-up the tendon structure was normal (no hypoechoic areas and regular structure) in 19 of the 26 tendons. Fahlström et al⁸ speculated that the eccentric training regimen might induce a response that normalizes the concentrations of glycosaminoglycans and possibly enables normalization of the fiber arrangement, resulting in decreased tendon thickness. In

this study, in most patients the pain in the tendon diminished and then disappeared during the 12-week treatment period. It is conceivable that the pain recedes during the early part of a possible remodeling phase, but normalization of tendon thickness and structure may be more time-consuming.

When no differences in effect can be found between treatment groups, one should always consider a type II error. However, a power analysis has shown that a minimum of 30 patients was needed to detect differences between eccentric training and no treatment. Another limitation is that from the present study, one cannot exclude the effects of placebo, similar in all 3 groups. However, a placebo group was not approved by our local ethics committee. Theoretically, there could be a risk for contamination between groups in randomized study. However, all patients of the heel brace group were instructed not to perform any kind of strengthening exercises on their own.

The limitations of the methods used in the present study inhibits our ability to draw any definite conclusions. This study could not demonstrate any significant differences between treatment with the AirHeel brace and an eccentric training program in patients with chronic Achilles tendon pain. No synergistic effects could be found when both treatment strategies were combined.

Further research is needed to evaluate whether the AirHeel brace is an alternative treatment option for patients with chronic Achilles tendinopathy.

ACKNOWLEDGMENT

The AirHeel brace was provided by Aircast Europe, Neubeuern, Germany.

REFERENCES

1. Alfredson H, Lorentzon R. Chronic Achilles tendinosis: recommendations for treatment and prevention. *Sports Med.* 2000;29:135-146.
2. Alfredson H, Pietilä T, Jonsson P, Lorentzon R. Heavy-load eccentric calf-muscle training for the treatment of chronic Achilles tendinopathy. *Am J Sports Med.* 1998;26:360-366.
3. Alfredson H, Thorsen K, Lorentzon R. In situ microdialysis in tendon tissue: high levels of glutamate, but not prostaglandin E2 in chronic Achilles tendon pain. *Knee Surg Sports Traumatol Arthrosc.* 1999;7:378-381.
4. Almekinders LC, Temple JD. Etiology, diagnosis, and treatment of tendonitis: an analysis of literature. *Med Sci Sports Exerc.* 1998;26:360-366.
5. Åström M, Rausing A. Chronic Achilles tendinopathy: a survey of surgical and histopathologic findings. *Clin Orthop Relat Res.* 1995;316:151-164.
6. Coull R, Flavin R, Stephens MM. Flexor hallucis longus tendon transfer: evaluation of postoperative morbidity. *Foot Ankle Int.* 2003;24:931-934.
7. Curvin S. Rehabilitation after tendon injuries. In: Mafulli N, Renström P, Leadbetter WB, eds. *Tendon Injuries.* New York, NY: Springer; 2005:242-266.
8. Fahlström M, Jonsson P, Lorentzon R, Alfredson H. Chronic Achilles tendon pain treated with eccentric calf-muscle training. *Knee Surg Sports Traumatol Arthrosc.* 2003;11:327-333.
9. James SL, Bates BT, Osternig LR. Injuries to runners. *Am J Sports Med.* 1978;6:40-50.

10. Järvinen M, Józsa L, Kannus P, Jarvinen TL, Kvist M, Leadbetter W. Histopathological findings in chronic tendon disorders. *Scand J Med Sci Sports*. 1997;7:86-95.
11. Józsa L, Kannus P. Human tendons. In: *Anatomy, Physiology, and Pathology*. Champaign, Ill: Human Kinetics; 1997.
12. Kavros S. The efficacy of a pneumatic compression device in the treatment of plantar fasciitis. *J Appl Biomech*. 2005;21:404-413.
13. Khan KM, Cook JL, Bonar F, Harcourt P, Astrom M. Histopathology of common tendinopathies. *Sports Med*. 1999;27:393-408.
14. Kitaoka HB, Alexander IJ, Adelaar RS, Nunley JA, Myerson MS, Sanders M. Clinical rating systems for the ankle-hindfoot, midfoot, hallux, and lesser toes. *Foot Ankle Int*. 1994;15:349-353.
15. Kvist M. Achilles tendon injuries in athletes. *Ann Chir Gynaecol*. 1991;80:188-201.
16. Leadbetter JD. The effect of therapeutic modalities on tendinopathy. In: Maffulli N, Renström P, Leadbetter WB, eds. *Tendon Injuries*. New York, NY: Springer; 2005:233-241.
17. Maffulli N. Rupture of the Achilles tendon. *J Bone Joint Surg Am*. 1999;81:1019-1036.
18. Maffulli N, Lorentzon R, Alfredson H. Superior short-term results with eccentric calf muscle training compared to concentric training in a randomized prospective multicenter study on patients with chronic Achilles tendinopathy. *Knee Surg Sports Traumatol Arthrosc*. 2001;9:42-47.
19. Maffulli N, Regine R, Angelillo M, Capasso G, Filice S. Ultrasound diagnosis of Achilles tendon pathology in runners. *Br J Sports Med*. 1987;21:158-162.
20. Martin RL, Manning CM, Carcia CR, Conti SF. An outcome study of chronic Achilles tendinopathy after excision of the Achilles tendon and flexor hallucis longus tendon transfer. *Foot Ankle Int*. 2005;26:691-697.
21. Movin T. *Aspects of Aetiology, Pathoanatomy and Diagnostic Methods in Chronic Mid-Portion Achillodynia* [dissertation]. Sweden: Huddinge Hospital/Karolinska Institute; 1998.
22. Movin T, Gad A, Reinholt FP. Tendon pathology in long-standing Achillodynia: biopsy findings in 40 patients. *Acta Orthop Scand*. 1997;68:170-175.
23. Öhberg L, Lorentzon R, Alfredson H. Neovascularisation in Achilles tendons with painful tendinopathy but not in normal tendons: an ultrasonographic investigation. *Knee Surg Sports Traumatol Arthrosc*. 2001;9:233-238.
24. Paavola M, Kannus P, Järvinen TAH, Khan K, Jozsa L, Jarvinen M. Achilles tendinopathy. *J Bone Joint Surg Am*. 2002;84:2062-2076.
25. Petersen W, Pufe T, Zantop T, Tillmann B, Tsokos M, Mentlein R. Expression of VEGFR-1 and VEGFR-2 in degenerative Achilles tendons. *Clin Orthop Relat Res*. 2004;420:286-291.
26. Pufe T, Petersen WJ, Mentlein R, Tillmann BN. The role of vasculature and angiogenesis for the pathogenesis of degenerative tendons disease. *Scand J Med Sci Sports*. 2005;15:211-222.
27. Pufe T, Petersen W, Tillmann B, Mentlein R. The angiogenic peptide vascular endothelial growth factor is expressed in foetal and ruptured tendons. *Virchows Arch*. 2001;439:579-585.
28. Roos EM, Engström M, Lagerquist A, Soderberg B. Clinical improvement after 6 weeks of eccentric exercise in patients with mid-portion Achilles tendinopathy: a randomized trial with 1-year follow-up. *Scand J Med Sci Sports*. 2004;14:286-295.
29. Silbernagel KG, Thomeé R, Thomeé P. Eccentric overload training for patients with chronic Achilles tendon pain: a randomised controlled study with reliability testing of the evaluation methods. *Scand J Med Sci Sports*. 2001;11:197-206.
30. Stanish W, Rubinovich M, Curvin S. Eccentric exercise in chronic tendinitis. *Clin Orthop Relat Res*. 1986;208:65-68.
31. Tallon C, Coleman BD, Khan KM, Maffulli N. Outcome of surgery for chronic Achilles tendinopathy: a critical review. *Am J Sports Med*. 2001;29:315-320.
32. Ware JE. *SF-36 Health Survey: Manual and Interpretations Guide*. Boston, Mass: The Health Institute, New England Medical Center; 1993.
33. Westphal T, Piatek S, Halm JP, Schubert S, Winckler S. Outcome of surgically treated intraarticular calcaneus fractures: SF-36 compared with AOFAS and MFS. *Acta Orthop Scand*. 2004;75:750-755.