

# Dilated Upper Sleeve Can be Associated with Severe Postoperative Gastroesophageal Dysmotility and Reflux

Andrei Keidar · Liat Appelbaum · Chaya Schweiger ·  
Ram Elazary · Aniceto Baltasar

Received: 31 January 2009 / Accepted: 10 November 2009  
© Springer Science+Business Media, LLC 2009

## Abstract

**Background** Laparoscopic sleeve gastrectomy (LSG) is an effective bariatric procedure, and it can be done as an isolated LSG or in conjunction with biliopancreatic diversion bypass/duodenal switch (laparoscopic duodenal switch; LDS). Gastroesophageal reflux after LSG has been described, but the mechanism is unknown and the treatment in the severest cases has not been discussed. We describe a cohort of patients who have underwent an LSG or LDS, and have suffered from a severe postoperative gastroesophageal motility disorder and/or reflux, report on their treatment, and discuss possible underlying mechanisms.

**Methods** Seven hundred and six patients underwent an LSG by two of the authors (AK, AB). Sixty nine patients underwent laparoscopic sleeve gastrectomy in Hadassah Medical Center, Jerusalem, Israel (January, 2006 and December 2008; 55 isolated LSG, 14 with LDS), and 637 (212 isolated LSG, 425 LDS) in Clinica San Jorge and Alcoy Hospital in Alcoy, Spain, (January 2002 and November 2008).

**Results** Of them, eight patients who has suffered from a gastroesophageal dysmotility and reflux disease postoperatively and needed a specific treatment besides regular proton pump inhibitors (PPIs) were identified (1.1%).

**Conclusion** A combination of dilated upper part of the sleeve with a relative narrowing of the midstomach, without complete obstruction, was common to all eight patients who suffered from a severe gastroesophageal dysmotility and reflux. The sleeve volume, the bougie size, and the starting point of the antral resection do not seem to have an effect in this complication. Operative treatment was needed in only one case out of eight; in the rest of the patients, medical modalities were successful. More knowledge is required to understand the underlying mechanisms.

**Keywords** Morbid obesity · Sleeve gastrectomy · Gastroesophageal reflux · Retained fundus · Gastroesophageal dysmotility

---

A. Keidar (✉) · R. Elazary  
Department of General Surgery,  
Hadassah-Hebrew University Medical Center,  
POB 12000, Jerusalem 91120, Israel  
e-mail: andreik@hadassah.org.il

L. Appelbaum  
Radiology Department, Hadassah Ein Kerem Medical Center,  
Jerusalem, Israel

A. Keidar · C. Schweiger  
Bariatric Surgery Service, Hadassah Ein Kerem Medical Center,  
Jerusalem, Israel

A. Baltasar  
San Jorge Clinic,  
Alcoy, Spain

## Introduction

Obesity is a worldwide epidemic disease. Bariatric operations for patients who suffer from morbid obesity are effective in reducing body weight and co-morbidities. Today, there is an arsenal of several surgical options for inducing weight loss.

Laparoscopic sleeve gastrectomy (LSG) can be done as an isolated LSG or in conjunction with biliopancreatic diversion bypass/duodenal switch (BPD/DS) laparoscopic duodenal switch (LDS) [1–3]. In the past, this procedure was presented as a modification of BPD and was combined with DS. Observations and studies have shown that patients who underwent this first-stage procedure achieved adequate weight loss [3]. According to this finding, LSG alone has

become a weight reduction procedure with low morbidity. LSG is very effective weight loss procedure, but its technical details are not standardized, and the morbidity varies widely between different series [3, 4]. Gastroesophageal reflux after LSG has been described, but the data are scarce, the mechanisms are largely unknown, and the optimal treatment in the severest cases, besides simple acid reducing strategies, has remained undiscussed. In this article, we describe a cohort of patients who have undergone LSG or LDS, and have suffered from a severe postoperative gastroesophageal dysmotility and/or reflux, report on their treatment, and discuss possible underlying mechanisms.

## Methods

### Patients

Seven hundred and six patients underwent an LSG by two of the authors (AK, AB). Sixty nine patients underwent laparoscopic sleeve gastrectomy in Hadassah Medical Center, Jerusalem, Israel (January, 2006 and December 2008; 55 isolated LSG, 14 with LDS), and 637 (212 isolated LSG, 425 with LDS) in Clinica San Jorge and Alcoy Hospital in Alcoy, Spain, (January 2002 and November 2008). Of them, eight patients who have suffered from a severe gastroesophageal dysmotility and reflux disease postoperatively and needed a specific treatment besides regular proton-pump inhibitors (PPIs) were identified (1.1%). The contrast swallow studies of all eight patients were significant for a wide, dilated fundus with a relatively narrow midstomach, but without complete obstruction.

All patients fulfilled criteria for bariatric surgery as coined by National Institutes of Health Consensus Conference. Our routine preoperative workup, besides the regular bariatric surgery candidate's battery, includes upper gastrointestinal barium (UGI) swallow studies in all patients operated by the first author, and on selective basis by the last author. Upper endoscopy was also done on a selective base whenever one of the following is positive for the presence of specific symptoms (heartburn, vomiting, etc.), positive past medical history (proton pump inhibitors treatment), or positive findings on UGI study. All patients were asked to fill in a structured questionnaire, with a specific query about known reflux disease or complaints of reflux symptoms. Patients who were upper gastrointestinal symptoms-free were not tested for the presence of *Helicobacter pylori* (HP). In six of the eight patients, preoperative UGI contrast study was performed, and all were normal. None of the eight patients has had any degree of clinical reflux preoperatively. Only one of the eight

patients included in the study has undergone an endoscopy preoperatively, due to the known peptic ulcer disease, and only this single patient (see further, Pt #3) was tested for HP infestation.

## Review of the Preoperative and Postoperative Data

The data was collected prospectively in all patients and fed into a computerized database. Every clinic visit and symptoms severity is documented through the structured questionnaire used routinely in the clinic. In many patients, the complaints of heartburn, vomiting, or inability to adequately progress to solid foods is encountered, but only the patients that required an additional treatment (above the regular follow-up and diet counseling) were included in this study. We defined the complaints as vomiting when voluminous projectile expulsion of the gastric content occurred and reflux whenever there was continuous expulsion of small amounts of clear mucous content with a sour taste as described by the patients. It seemed that hypersalivation contributed gravely to this phenomenon.

The postoperative day (POD) 1 upper GI contrast studies with a water-soluble material of all 706 patients were reviewed by a radiologist and attending surgeon in order to detect the radiologic features that characterize this cohort of eight patients.

## Surgical Procedures

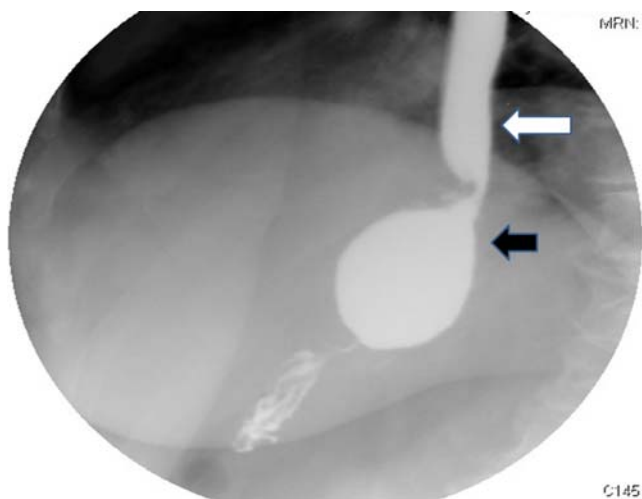
LSG was performed using five ports. The omentum adjacent to the whole length of the greater curvature and splenic short gastric vessels were divided by Harmonic scalpel (Ethicon Endosurgery, Cincinnati, OH, USA). Different sizes of bougie were inserted to the pylorus. Longitudinal stomach division was done starting at 2–4 cm proximally to the pylorus by consecutive application of an endoscopic stapler (blue and green load, EndoGIA 45 mm or Echelon golden load, Ethicon Endosurgery) parallel to the bougie, up to the gastro-esophageal junction. In none of the patients, staple line buttressing material was used. Gastric tube (sleeve) <60–80 cc in volume was constructed, and the remaining >80% of stomach was excised. The staple line was routinely inverted by placing a sero-serosal continuous suture of polydioxanone in patients operated by the last author, but only in selected cases (where there was an excessive bleeding from the staple line or serosal tears, or any suspicion of inadequate closure) by the first one. Both surgeons perform oversawing of the staple line before the bougie removal. Diluted half-strength methylene blue dye (50 cc) was used to test for leaks. The duodenum was clamped, and by irrigating the sleeve, the dye usually

overflowed back to the patient's mouth. The stomach was removed by enlarging the peritoneal and fascial opening of the 12-mm trocar and by pulling from the antrum without the need for a protecting bag. The enlarged fascial opening was closed with a single figure-of-eight Maxon No. 1 suture, and a drain was left along the suture line through one 5-mm port for 2 days. On postoperative day 1, the patients underwent Gastrografin® X-ray study to rule out leaks, and if negative, started on sips of clear liquids. None of these tests showed an obstruction on the POD 1 contrast swallow studies. Only five out of the eight patients included in the study were treated from the first postoperative day by PPIs, but once their symptoms occurred, all of them were started on a high dose of the medication.

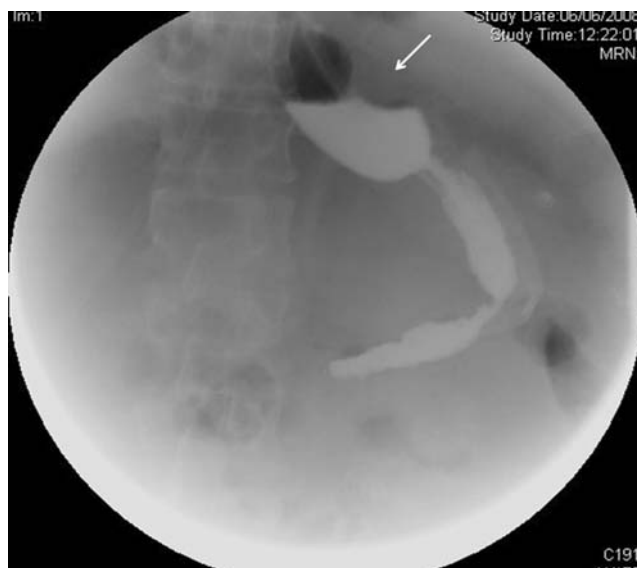## Results

### Patient 1

BS is a 59-year-old lady with a body mass index (BMI) of 41, severe hip osteoarthritis and hyperlipidemia, underwent LSG over a Bougie of 32 F (French), and gastric resection starting at 4 cm proximal to the pylorus. Only the distal part of the staple line was oversawn, due to bleeding. Postoperative stay was 4 days, but she was rehospitalized on POD 12 due to continuous vomiting. Swallow study revealed a dilated upper part of the sleeve (Fig. 1), with an immediate passage to the lower part and duodenum, though the middle part of the sleeve was significantly narrower, and the contrast has retained in the fundus area, which was relatively dilated. Due to a suspicion that there is an edema of the sleeve, she was treated with naso gastric drainage and



**Fig. 1** UGI study revealing a dilated upper part of the sleeve (*black arrow*), with an immediate passage to the lower part. The contrast has retained in the fundus area and reflux up to the mid esophagus was observed (*white arrow*)



**Fig. 2** UGI study revealing a dilated upper part of the sleeve (*white arrow*), with free passage to the lower part

intravenous Ranitidine for 1 week, but repeated attempts to start drinking while on full dose of metoclopramide failed. Three weeks later she underwent an endoscopy. Normal pliable stomach with sort of kinking point at the mid-sleeve was demonstrated, which was passed easily through with an endoscope. Severe esophagitis was also noted. Balloon dilatation to 15 mm was performed. The next day, the patient was started on full dose of oral PPIs and clear fluids, and tolerated them well. Today, 30 month after the procedure, her BMI is 30, she has no reflux, and completely asymptomatic.

### Patient 2

CC is a 52-year-old male with BMI of 47, suffering from severe obstructive sleep apnea, diabetes, hypertension, and hyperlipidemia. He underwent LSG with a bougie of 32 F, gastric resection started at 1 cm from the pylorus, without staple line oversawing. Because of severe sleep apnea, he was treated with continuous positive airway pressure, with a stay of 5 days, with uneventful recovery. He returned to emergency room (ER) on postoperative day 15 because of acute renal failure discovered because of blood tests that were done due to recurrent vomiting. At that time, he has already lost 18 kg since the operation. The contrast swallow study showed a wide upper sleeve, but otherwise immediate and free passage of the contrast to the duodenum (Fig. 2).

He was treated with full-dose PPIs starting from the procedure. Nutritional assessment revealed multiple vomiting after each meal or drinking attempt. After several days of rehydration and fasting and rigorous nutritional counseling, cautious oral intake was reinstated. Vomiting frequency

decreased significantly, and he was discharged. Vomiting frequency decreased gradually, and stopped. One year postoperatively, he is asymptomatic with a BMI of 36.

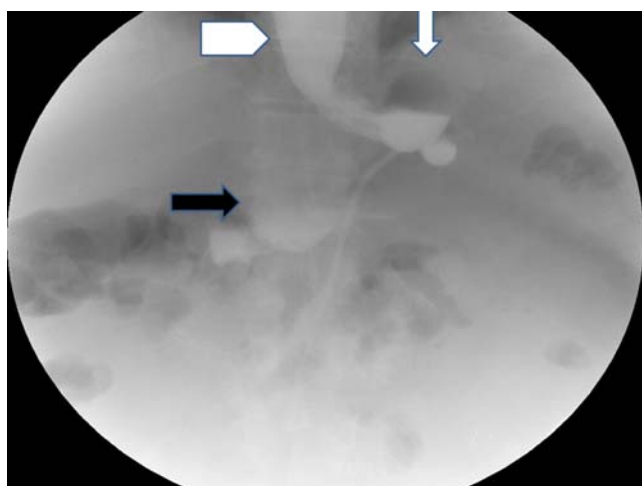
#### Patient 3

IR is a 47-year-old male with a preoperative BMI of 45. His comorbidities included hypertension and hyperlipidemias. He has had an active duodenal ulcer disease with positive *Helicobacter pylori*, for which he was treated with full-dose PPIs and triple antibiotic therapy and on repeated endoscopy, the ulcer has healed. He has had an LSG over a 32 F bougie with the beginning of stomach resection at 1 cm from the pylorus.

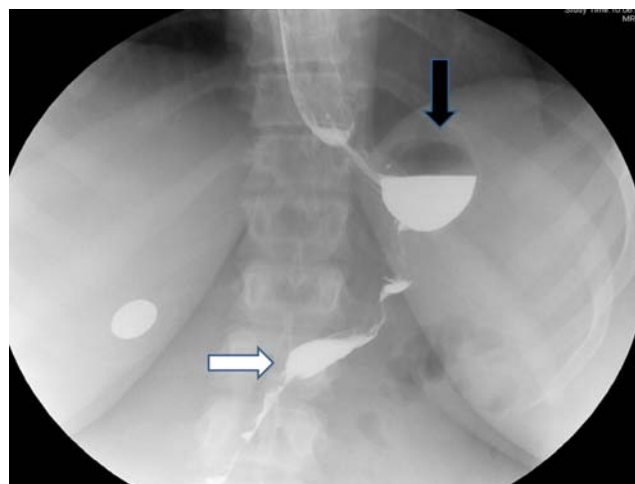
His postoperative swallow study showed large upper part of the sleeve, with normal emptying into the distal parts and further to the duodenum (Fig. 3). His hospital stay was 3 days. After discharge, he started complaining of disabling reflux. He continued treatment by PPIs and despite all possible behavioral means, his life was miserable because he couldn't sleep due to constant regurgitations and vomiting and cough. After 2 months of constant counseling, there was an improvement and now, 8 month after surgery, there are only mild reflux symptoms left and his BMI is 32.

#### Patient 4

A 32-year-old woman with a BMI of 39 presented to us after failure of two previous operations—gastric banding and sleeve gastrectomy. Her preoperative UGI series showed a very large sleeve. She underwent laparoscopic re-sleeve gastrectomy with duodenal switch, over bougie of 40 F and resection from 2 cm proximal to pylorus. The



**Fig. 3** UGI study revealing a dilated upper part of the sleeve (*white arrow*) with free passage to the lower part (*black arrow*) and reflux of contrast to the esophagus (*white arrowhead*). A JP catheter is observed in the left upper abdomen next to the stomach



**Fig. 4** UGI study revealing a dilated diverticulum-like upper part of the sleeve (*black arrow*) with free passage to the lower part (*white arrow*) and immediate emptying through the duodenoileal anastomoses, but contrast retention in the upper part

whole length of the staple line was oversawn while the bougie is still in the stomach. Because of severe adhesions at the area of gastro-esophageal junction (GEJ), the upmost part of the sleeve remained untouched and, on the postoperative swallow, it remained wide, and the emptying into the rest of the sleeve was slow. Postoperatively, she suffered from recurrent vomiting, and repeated swallow study showed the same wide upper part of the sleeve. There was immediate and good emptying into the duodenum, but, at the same time, retention of some contrast in the upper part. Three weeks after the operation, upper endoscopy was performed, with an intention to dilate the narrow part, but it showed no significant narrowing. The patient continued suffering from constant vomiting and regurgitation, awakening her at night with mouth full of sour juice. At 2 months after the operation, she has lost 25 kg, and still has been vomiting after every meal. She was hospitalized for an investigation, and developed clinical picture of vitamin B1 deficiency, with prominent proximal muscle weakness and diplopia. Level of clinical suspicion was high, and she was treated without ever arriving at a biochemical diagnosis of thiamin deficiency. Although there was a quick passage of the contrast through the sleeve on the repeated swallow study, there was also retention of the material in the upper dilated part of the stomach (Fig. 4). She was treated by endoscopic dilatation, and after that there was a gradual improvement in her ability to eat. Her BMI now is 24.1

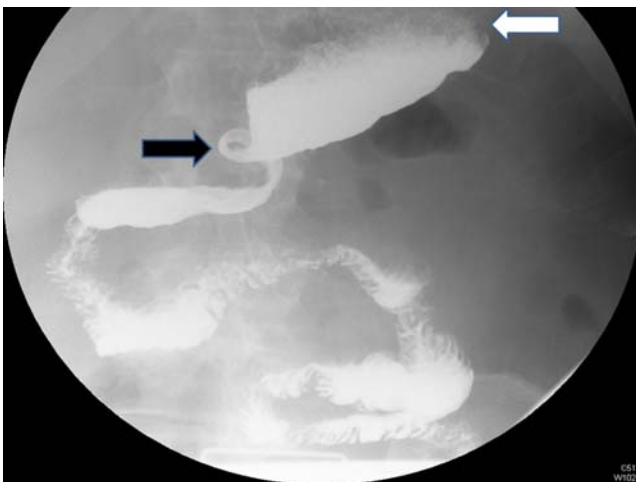
#### Patient 5

SD is a 72-year-old patient with a BMI of 40 with diabetes, hypertension, and sleep apnea who underwent LSG over a 32 F bougie with the beginning point of antral resection of

2 cm proximal to pylorus. His POD 1 contrast swallow was normal, but 3 days later, he developed aspiration pneumonia after several episodes of vomiting. He recuperated well and was discharged on POD 10. During the following 2 months, his life was a nightmare due to a constant vomiting, sometimes with a coffee ground-like content. He was admitted three times to the ER for rehydration, and he also was kept on intravenous fluids and nil per os (NPO) for a period of 10 days during which, he did not suffer from not even a single vomiting. Two and a half months later, he was admitted to the hospital and a swallow study has shown a dilated upper part of the sleeve containing food particles and a fairly good passage to the rest of the stomach (Fig. 5). An endoscopy was performed, but the endoscope passed easily through the sleeve. There was dilation of the upper part of the sleeve. Esophageal manometry showed an absence of peristalsis in the esophageal body and low lower esophageal sphincter (LES) pressure. He was treated with motilium (Domperidone) and high-dose PPIs with no relief. Balloon dilatation was performed at the relatively narrow part of the sleeve with a 20 mm balloon. After dilatation, he was put on erythromycin 250 mg three times a day (TID), and started progressing slowly but steadily on oral intake, and now, 5 months after the operation, his condition is gradually improving. His BMI now is 25.

#### Patient 6

A 36-year-old male, BMI-47 without comorbidities, had an uneventful LSG over the 32 French bougie, associated with BPD/DS. He was vomiting on and off for 1 month until the diagnosis of fundus diverticula (which represents retained



**Fig. 5** UGI study revealing a dilated upper part of the sleeve containing food particles (*white arrow*), with free passage to the lower part and duodenum (*black arrow*)

part of the fundus) was made (Fig. 6). A feeding nasogastric (NG) tube was used for 20 days and then the patient was able to feed himself with the NG tube on, until finally the tube was removed 5 days later. He has remained asymptomatic till today with a BMI of 32.

#### Patient 7

TH was a 60-year-old male with BMI 42, with diabetes, hypertension, hypertriglyceridemia, and a coronary stent, operated with a LDS. The patient developed an untreatable gastroparesis and was managed with naso-enteral feeding. BMI dropped from 42 to 30 (%EBMIL 68%), and a total gastrectomy was undertaken. Postoperatively, abdominal bleeding occurred, which was treated successfully with blood and platelet transfusion. He had leaks at the two entero-enterostomies that required laparotomy and redo of both anastomoses and secondary closure of the abdominal wall. He is now asymptomatic.

#### Patient 8

EN is an 18-year-old healthy female with a BMI of 42, who underwent LSG with a bougie of 32 French and stomach resection 2 cm from the pylorus. She has had difficulties since the very operation, but stayed at fluids for the whole first month. She was admitted, and stayed on NPO for 1 week, without any improvement. Oral erythromycin 250 TID and motilium 20 mg TID were started, without any relief. Upper endoscopy showed dilated upper pouch, and area of kinking at the midstomach, easily passable by the endoscope. Balloon dilatation up to the 18 mm did bring some relief. She is asymptomatic now.

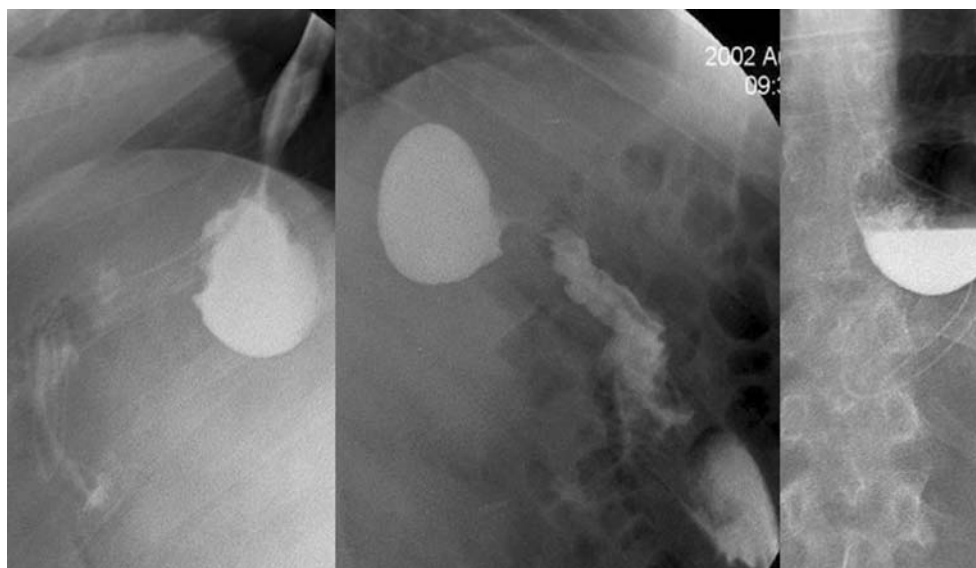
## Discussion

LSG operation is becoming an important modality in the armamentarium of bariatric surgery. The mechanisms for the weight loss are restriction of the gastric capacity and passage of food through the stomach. Other mechanism which is widely investigated is reduction of ghrelin level, probably incited by the excision of the gastric fundus. Besides the common surgical adverse effects of the procedure (leaks, bleedings, and strictures), an unexplained raise in the incidence of gastroesophageal reflux has been reported [3–5].

### Incidence and Possible Mechanisms of Reflux After LSG

We believe that this problem is underestimated, especially in light of its very wide clinical spectrum of manifestation. There is probably a continuum from mild reflux that may

**Fig. 6** Retained fundus functioning as diverticula



well respond to PPIs, through severe symptomatic reflux that may need a deployment of full treatment armamentarium (high-dose PPIs, propulsive medications, and behavioral and lifestyle changes) in order to overcome it, to the complete inability to ingest oral food, that may require hospitalization for assisted feeding and reoperation.

Therefore, the true incidence of this complication after sleeve gastrectomy is not known. The works that do report the incidence cite numbers from as low as 0.1% for prolonged vomiting, 0.2% for delayed gastric emptying [4], to as high as 13–30% [5, 6]. In other series, it is not mentioned at all, but some patients are reported to be readmitted for dehydration and renal failure, both of which may possibly be related to the postoperative gastroesophageal reflux disease. Even Wernicke–Korsakoff syndrome has been reported after sleeve gastrectomy (SG) due to prolonged vomiting [7]. This wide variation in incidence reported makes us to suppose that the criteria for diagnosing this complication are different. Most authors report of prescribing PPIs for different periods of time to the SG patients [3].

There are several reports about remedial operation required for severe reflux, vomiting, and inability to tolerate oral intake. Makarewitch [7] reported a conversion of the sleeve to a mini-gastric bypass as a minimal possible procedure. Gagner [8] described re-sleeve gastrectomy and hiatal hernia repair after duodenal switch for a patient with severe reflux, hiatal hernia, and weight regain.

Serra described a patient who underwent a total gastrectomy for gastric paresis after duodenal switch procedure [9].

The exact mechanism of this reflux complication is not clear. Impaired gastric emptying may be a possible explanation. Himpens [5] and Weiner [10] evaluated the incidence of reflux, and found that it increases during the first postoperative year, but disappears thereafter. Does it

expose the preexistent subtle dysmotility of the stomach or esophagus or there is some intrinsic effect of the procedure itself? It is mainly unknown how this operation affects gastric emptying, and the only two studies published on this issue reported controversial results. The Melissas's study [11] reported an increase in the gastric clearance times, while Bernstine et al. cited no change in gastric emptying rates at 3 months after the operation [12]. Carmichael [13] describes a delay in gastric emptying after Magenstrasse and Mill operation, although that is not exactly the same operation. In our series, most of the patients have had the antrum resected starting from 2 cm from pylorus. Some authors [10] suggested that leaving the antral part behind is crucial for normal function of the retained stomach, but they themselves report reflux with a technique of resection that starts from 5–6 cm proximal to pylorus, so we suggest that the extent of the resection of the antrum has no implication on the sleeve emptying.

Anatomical changes in the angle of His and GEJ area and retention of the fundus may play an important role in the postoperative sleeve emptying. The more fundus left behind, the higher the propensity of the stomach to distend, especially in view of a functional obstruction. Larger retained fundus will produce more gastric acid, and this in turn may result in larger amount of acid available for refluxing into the esophagus. It is clear that in cases where the fundus has been left behind, the anatomy of the gastroesophageal junction was disturbed to a lesser degree, and this contradicts the supposition that disturbance of this area is a culprit. Moreover, some surgical procedures involve complete dissection of the area of LES (paraesophageal hernia repair), and even if done without a fundoplication, they do not necessarily exacerbate reflux.

Does the volume of the retained stomach (sleeve) affect the incidence or severity of reflux? Different series report

about this manifestation independently of the sizes of the bougie used. In our series, complete or partial staple line oversawing was used in four out of eight patients. Therefore, size of the gastric tube and oversawing the staple line did not seem to affect the rate of reflux.

In order to identify if dilated fundal part and relative distal narrowing are the distinguishing features of the reflux symptoms, all POD 1 swallow studies were reviewed by the rentgenologist and surgeon. In none of them was an isolated dilated fundus found. Probably the most important aspect of this finding is not the degree of fundal dilatation, but the presence of a relative narrowing distal to it. This relative narrowing impairs the emptying from the fundal part of the sleeve. The ways in which this narrowing can be inflicted at surgery may include a construction of too narrow a sleeve while using a small bougie, overdue tension on the stomach in an attempt to approximate the bougie closer to the lesser curvature, or oversuturing of the sleeve with overly deep bites. The fundal dilatation probably represents the retention of the fundus at the operation while trying to avoid the injury to the area of the esophagogastric junction or incomplete release of the posterior fundus. It seems that this complication occurs whenever there is a combination of upper fundal part of the sleeve is left behind, and there is a relative narrowing of the more distal part, without a complete obstruction.

#### Treatment Options

Treatment options are divided into conservative therapy, endoluminal modalities, and surgical options. Obviously, the simple fibrotic stricture or complete obstruction should be excluded by swallow study or endoscopy. But even in the absence of complete anatomical occlusion, there may be a functional obstruction, where the propulsive force of the stomach and esophagus is not enough to clear the content downstream. In those cases, endoscopic dilatation may be beneficial, as it was the case in all three of our patients who underwent the dilatation. We do not know if this is the coincidence or a real improvement in the emptying ability of the sleeve.

Conservative measures are directed at reducing acid production and improvement of gastric and esophageal motility and acid clearance. Psychological and diet counseling are of utmost importance on the way to success.

New endoluminal therapy is developing with several techniques available; the most promising is Stomaphyx, creating an endoluminal cuff by stomach plication.

Surgical options can be directed at improvement of gastric emptying and decrease of acid production. Since there is no fundic tissue available, the possibility of fundoplication is nonexistent. Ligamentum teres cardiopexy has been described [7]. Re-sleeve will decrease the acid

production, but there are no studies reporting objective data of the gastric acidity before and after the sleeve gastrectomy. The best possible operation is probably a conversion to Roux-en-Y gastric bypass, the procedure that will improve emptying and divert the acid gastric content to the small bowel. The question is open if a smallest possible gastric pouch should be left or the anastomoses should be between the esophagus and a Roux limb to completely avoid regurgitation of the gastric juice. Obviously, this can be done with or without total gastrectomy of the sleeve. A seromyotomy is an alternative for the mechanical and anatomical stenosis of the sleeve [14].

#### Conclusion

Obviously, there are several flaws to this study. The preoperative evaluation is not standardized and some patients lack preoperative data on *Helicobacter pylori* infection. The operative technique was somewhat different between patients, and postoperative treatment with PPIs was not uniform. Therefore, firm conclusions are impossible to make.

Since sleeve gastrectomy is a novel technique, the knowledge regarding the influence of the operation on the gastroesophageal function is scarce. More investigations regarding the physiology of the procedure in terms of emptying, acid production, and reflux mechanisms are needed to draw more conclusions. Until that knowledge is available, a cautious approach to the patients with preoperatively suspected motility disorders should be exercised. Patients suspected to have this kind of dysfunction should be studied by esophageal manometry or nuclear emptying studies and may be other operative technique suggested. Patients should be advised preoperatively about the possibility of this complication. If this complication has occurred, conservative approach is usually successful, but sometimes, a conversion to other procedure can be curative.

**Disclosure** Authors have no disclosure to make.

#### References

1. Iannelli A, Dainese R, Piche T, et al. Laparoscopic sleeve gastrectomy for morbid obesity. *World J Gastroenterol.* 2008;14:821–7.
2. Gumbs AA, Gagner M, Dakin G, et al. Sleeve gastrectomy for morbid obesity. *Obes Surg.* 2007;17:962–9.
3. Deitel M, Crosby RD, Gagner M. The First International Consensus Summit for Sleeve Gastrectomy (SG), New York City, October 25–27, 2007. *Obes Surg.* 2008;18:487–96.

4. Frezzo EE, Freddy S, Lee LL, et al. Complications after sleeve gastrectomy for morbid obesity. *Obes Surg.* 2009;19(6):684–7.
5. Himpens J, Dapri G, Cadiere G. A prospective randomized study between laparoscopic gastric banding and laparoscopic isolated sleeve gastrectomy: results after 1 and 3 years. *Obes Surg.* 2006;16:1450–6.
6. Hamoui N, Anthone G, Kaufman H, et al. Sleeve Gastrectomy in high-risk patients. *Obes Surg.* 2006;16:1445–9.
7. Makarewicz W, Kaska L, Kobiela J, et al. Wernicke syndrome after sleeve gastrectomy. *Obes Surg.* 2005;17:704–6.
8. Parikh M, Gagner M. Laparoscopic hiatal hernia repair and repeat sleeve gastrectomy for gastroesophageal reflux disease after duodenal switch. *Surg Obes Rel Dis.* 2008;4:73–5.
9. Serra C, Baltasar A, Pérez N, et al. Total gastrectomy for the complications of the duodenal switch, with reversal. *Obes Surg.* 2006;16:1082–86.
10. Weiner RA, Weiner S, Pomhoff I, et al. Laparoscopic sleeve gastrectomy—influence of sleeve size and resected gastric volume. *Obes Surg.* 2007;17:1297–305.
11. Melissas J, Koukouraki S, Askoxylakis J, et al. Sleeve gastrectomy: a restrictive procedure? *Obes Surg.* 2007;17:57–62.
12. Bernstine H, Tzioni-Yehoshua R, et al. Gastric emptying is not affected by sleeve gastrectomy a scintigraphic evaluation of gastric emptying after sleeve gastrectomy without removal of the gastric antrum. *Obes Surg.* 2009;19(3):293. doi:10.1007/s11695-008-9791-5.
13. Carmichael AR, Johnston D, Barker MCJ, et al. Gastric emptying after a new, more physiological anti-obesity operation: the Magenstrasse and Mill procedure. *Eur J Nucl Med.* 2001;28:1379–83.
14. Dapri G, Cadiere GB, Himpens J. Laparoscopic seromyotomy for long stenosis after sleeve gastrectomy with or without duodenal switch. *Obes Surg.* 2009;19(4):495–9.