

European consensus document on mast cell tumours in dogs and cats

L. Blackwood^{1,†}, S. Murphy^{2,†}, P. Buracco³, J. P. De Vos⁴,
P. De Fornel-Thibaud⁵, J. Hirschberger⁶, M. Kessler⁷, J. Pastor⁸,
F. Ponce⁹, K. Savary-Bataille¹⁰ and D. J. Argyle¹¹

¹Small Animal Teaching Hospital, The Leahurst Campus, University of Liverpool Chester High Road, Neston Wirral CH64 7TE, UK

²The Animal Health Trust, Suffolk CB8 7UU, UK

³Department of Animal Pathology, School of Veterinary Medicine, University of Turin, Grugliasco (TO), Italy

⁴“De Ottenhorst” Veterinary Oncology Referral Centre, Terneuzen, The Netherlands

⁵DESV Internal Medicine, Centre de Cancérologie Vétérinaire, Maisons-Alfort, France

⁶Medizinische Kleintierklinik Clinic for Small Animal Medicine, Center for Clinical Veterinary Medicine, Ludwig-Maximilians-Universität München Veterinärstr, München, Germany

⁷Tierklinik Hofheim, Hofheim, Germany

⁸Patología Médica Facultad de Veterinaria, Universidad Autónoma de Barcelona, Bellaterra, Spain

⁹VetAgro Sup, Université Lyon 1, Lyon, France

¹⁰Pfizer Animal Health EUAfME, Paris, France

¹¹Royal (Dick) School of Veterinary Studies and Roslin Institute, Easter Bush Midlothian EH25 9RG, UK

1 Abstract.....	e2
2 Introduction	e3
2.1 Background	e3
2.2 Evidence-based medicine (EBM)	e3
2.2.1 EBM grading system	e3
3 Biology and function of mast cells.....	e3
4 Canine MCT.....	e4
4.1 Incidence and signalment	e4
4.2 Clinical presentation	e4
4.2.1 Lesion	e4
4.2.2 Clinical behaviour	e4
4.2.3 Paraneoplastic disease	e5
4.3 Diagnostic approach.....	e5
4.3.1 Fine needle aspirate.....	e5
4.3.2 Incisional biopsy	e6
4.3.3 Excisional biopsy.....	e6
4.4 Staging.....	e6
4.5 Prognosis.....	e7
4.5.1 Histopathology.....	e8
4.5.2 Lymph node pathology	e8
4.5.3 Anatomic location	e8

Correspondence address:
David J. Argyle
Royal (Dick) School of
Veterinary Studies and
Roslin Institute
Easter Bush, Midlothian
EH25 9RG, UK
e-mail:
David.argyle@ed.ac.uk

[†] L. B. and S. M. contributed equally and are joint first authors.

4.5.4 Clinical features	e9
4.5.5 Treatment failure	e9
4.5.6 c-Kit expression	e9
4.5.7 Proliferation markers.....	e9
4.6 Subcutaneous MCT in dogs	e10
4.7 Treatment.....	e10
4.7.1 Surgery	e10
4.7.2 Radiotherapy	e13
4.7.3 Chemotherapy	e14
4.7.4 Tyrosine kinase inhibitors	e16
4.7.5 Other treatments	e20
4.7.6 Immunotherapy.....	e20
4.7.7 Supportive therapy	e21
4.8 Quality of life	e21
5 Feline mast cells tumours	e21
5.1 Clinical presentation	e21
5.2 Clinical examination, biopsy and staging	e22
5.3 Prognosis.....	e22
5.4 Treatment.....	e22
5.4.1 Surgery	e22
5.4.2 Supportive therapy	e23
5.4.3 Radiotherapy	e23
5.4.4 Chemotherapy	e23
5.4.5 Tyrosine kinase inhibitors	e23
6 Acknowledgement	e23

Statement from the Authors

In preparing this document the Authors aimed to pool current information on canine and feline mast cell disease. The information was gathered from international studies and a emphasis was placed on material and opinion with a strong evidence base. We intend it to form the basis of our understanding in this disease at the current time and we anticipate that it will be particularly useful for the general practitioner. It should be emphasized that the authors are presenting this work from a European perspective.

1 Abstract

Mast cell tumours (MCT) are commonly encountered in small animal practice. This review outlines the biology of mast cell disease, the physiological consequences of MCT and offers a 'best practice' approach to clinical management of dogs and cats with mast cell disease. Diagnostic tests, conventional management and novel treatments are discussed, and evidence-based recommendations are given.

Keywords

cat, consensus management, diagnosis, dog, mast cell tumor, prognostic factors, treatment

Key Points

- Mast cell disease is a common disease of dogs and should always be considered in the list of differential diagnoses for a skin mass.
- Mast cell tumours can give rise to paraneoplastic disease associated with histamine or heparin release from degranulating tumours.
- Diagnosis can be made by fine needle aspirate (FNA).
- Grade of the tumour is an important prognostic marker.
- The primary treatment modality for mast cell tumours is surgery.
- Radiation treatment is usually reserved as an adjunct to surgery where complete excision cannot be achieved.
- Chemotherapy is used to:
 - Reduce tumour burden prior to definitive surgery
 - In high grade tumours or where there is evidence of systemic spread
 - Postoperatively where a tumour has been incompletely excised and a further surgery is not possible or radiation therapy is not available.
- Tyrosine kinase inhibitors are a new class of drug that may be used in instances of nonresectable or recurrent mast cell disease where conventional therapy is not appropriate or available.

2 Introduction

2.1 Background

In March 2009, after a series of meetings and the approval of the first receptor tyrosine kinase (RTK) inhibitor drugs for the management of MCT, the authors initiated this clinical guide to 'best practice' in the management of canine and feline MCT. Statements in these guidelines are based on published papers, consensus opinion and the authors' own expert opinions.

2.2 Evidence-based medicine (EBM)

Individual references used to support statements were classified according the scheme below. Where multiple references were available, those with the highest evidence level were cited. Where peer-reviewed sources were lacking, statements are the opinion of the authors (EBM grade IV).

2.2.1 EBM grading system

The grading system proposed by Roudebush *et al.*¹ is used:

Grade I: At least one properly designed, randomized controlled clinical study performed in the target species.

Grade II: Evidence from properly designed randomized controlled studies in animals of the target species with spontaneous disease in a laboratory or research animal colony setting.

Grade III: Appropriately controlled studies without randomization; appropriately designed case-control epidemiologic studies; studies using models of disease or simulations in the target species; dramatic results from uncontrolled studies; case series.

Grade IV: Studies conducted in other species; reports of expert committees, descriptive studies; case reports; pathophysiologic justification; opinions of respected experts.

3 Biology and function of mast cells

Mast cells arise as precursors in the bone marrow and then migrate to the peripheral tissues where, under the influence of local cytokines, they differentiate into mature mast cells. In normal animals, mast cells are present in most tissues, especially where the body meets the environment (skin, mucosal surfaces). They are occasionally seen in the bone marrow, but almost never in the systemic circulation.²

Mast cells contain cytoplasmic granules harbouring a large number of bioactive constituents, such as histamine and heparin, involved in hypersensitivity, allergy and inflammatory processes. These granules stain metachromatically with toluidine blue.^{2,3}

Mast cell tumours (MCT) are neoplastic proliferations of mast cells. Cutaneous MCT arise from tissue mast cells in the dermis and subcutaneous tissues.

4 Canine MCT

4.1 Incidence and signalment

MCT account for 16–21% of skin neoplasms in dogs. Tumours are usually solitary, though a significant proportion of dogs present with multiple tumours. MCT usually occur in older dogs (mean age 9 years), but may occur in dogs under 1 year of age also. There is no gender predilection. Boxers, Retrievers, Pugs, Boston terriers and Pit-Bull terriers are at a higher risk of developing MCT. However, in Boxers and Pugs, MCT are commonly histologically low or intermediate grade, carrying a more favourable prognosis. Shar-Peis, particularly young individuals, are also predisposed to developing MCT, and these are often poorly differentiated and biologically aggressive^{4–8} (EBM III). The aetiology of MCT in the dogs is unknown.

4.2 Clinical presentation

4.2.1 Lesion

MCTs may develop anywhere on the body, and are usually cutaneous (dermal) or subcutaneous. Various forms exist:

Well-differentiated cutaneous MCT are slow growing, hairless, solitary lesions and are often present for months (Panel 1A).

Poorly differentiated MCT are rapidly growing, ulcerated and pruritic lesions sometimes with small 'satellite lesions' close by (Panel 1B). There may be evidence of local lymphadenopathy or organomegaly on abdominal palpation.

A significant minority of **subcutaneous** MCT look and feel like lipomas (Panel 1C).

Some 10–21% of dogs develop **multiple primary** MCT either at initial presentation or as subsequent events (EBM III).^{8–11} Care should be taken to distinguish these dogs from those suffering from regrowth or a poorly differentiated tumour with satellite lesions.

4.2.2 Clinical behaviour

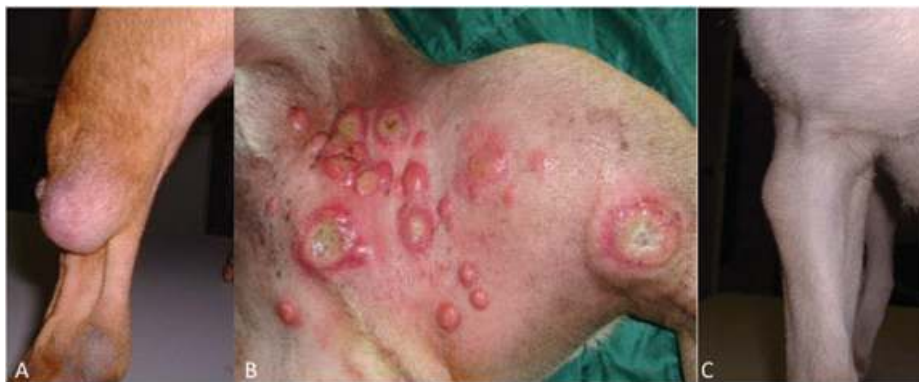The gross appearance of MCTs correlates to some extent with histological grade, and a tumour that looks aggressive is almost certainly aggressive, but a tumour that appears quiescent should not be assumed to be benign. Clinical signs suggestive of aggressive behaviour include (EBM III)^{6,8}:

- (1) Rapid growth
- (2) Local irritation/inflammation
- (3) Local infiltration/poor demarcation from adjacent tissues
- (4) Ulceration
- (5) Satellite nodules
- (6) Paraneoplastic signs.

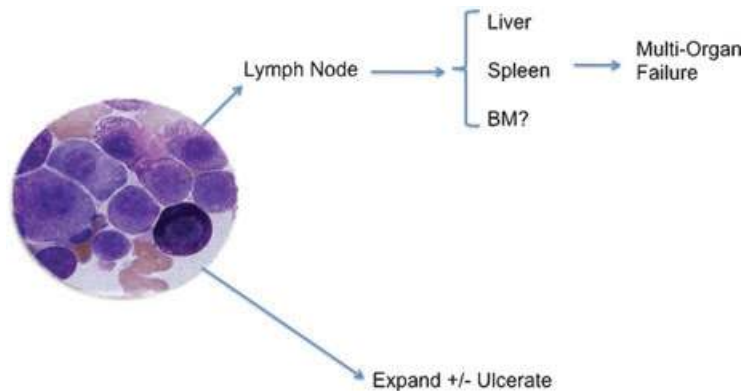
MCT that remain localized and are present for prolonged periods (months to years) without significant changes are usually benign¹² (EBM III).

Occasionally, manipulation during examination may cause mast cell degranulation, producing erythema and wheal formation, the so-called 'Darier's sign'.

MCT occur infrequently in mucosal sites. Rarely, dogs present with disseminated or systemic



Panel 1. Examples of the clinical appearance of canine MCT. Well differentiated MCT (A), Poorly differentiated MCT (B) and subcutaneous MCT (C).



Panel 2. The natural history of canine MCT. Growth of the tumour can cause local ulceration and swelling. Spread of the tumour is normally to local lymph nodes and ultimately to liver and spleen.

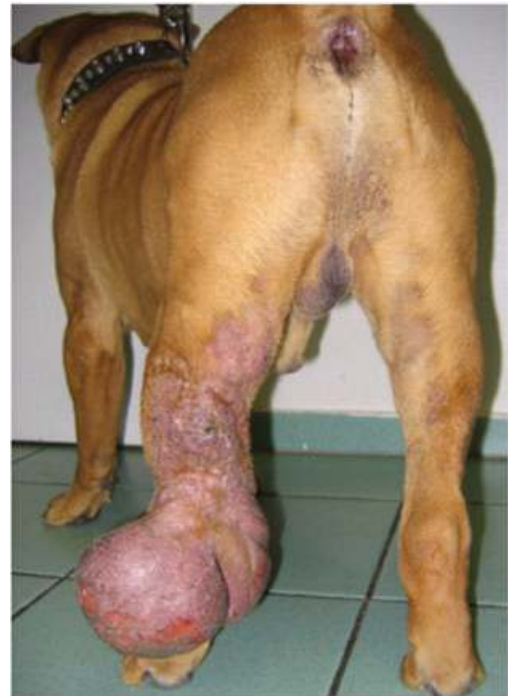mastocytosis, affecting lymph nodes, spleen, liver and bone marrow. The natural history of canine MCT is depicted in Panel 2.

4.2.3 Paraneoplastic disease

Dogs may present with so-called paraneoplastic clinical signs, due to the release of bioactive constituents, such as histamine, heparin and proteases from mast cell granules (EBM III).^{4,6–8} Locally, these substances cause oedema, ulceration and swelling at the primary tumour site, and possibly delayed wound healing and local coagulation abnormalities (Panel 3).

The most common systemic effects are gastrointestinal (GI) signs. Histamine released by neoplastic mast cells stimulates gastric H₂ receptors, leading to hydrochloric acid oversecretion and gastric hypermotility (EBM III).¹³ Clinical signs secondary to ulceration include vomiting, GI haemorrhage, anorexia and abdominal pain. Secondary iron deficiency anaemia or peritonitis due to GI perforation may occur. Necropsy studies report GI ulceration in 35–83% of MCT patients (EBM III).¹⁴

Rarely, a sudden, massive release of histamine from neoplastic cells may cause an acute anaphylactic reaction, and episodes of collapse. Dogs with extensive disease are particularly at risk.



Panel 3. Mast cells contain vasoactive granules. Degranulation in mast cell tumours can cause localized swelling, oedema and bleeding. In severe cases this can cause systemic anaphylaxis.

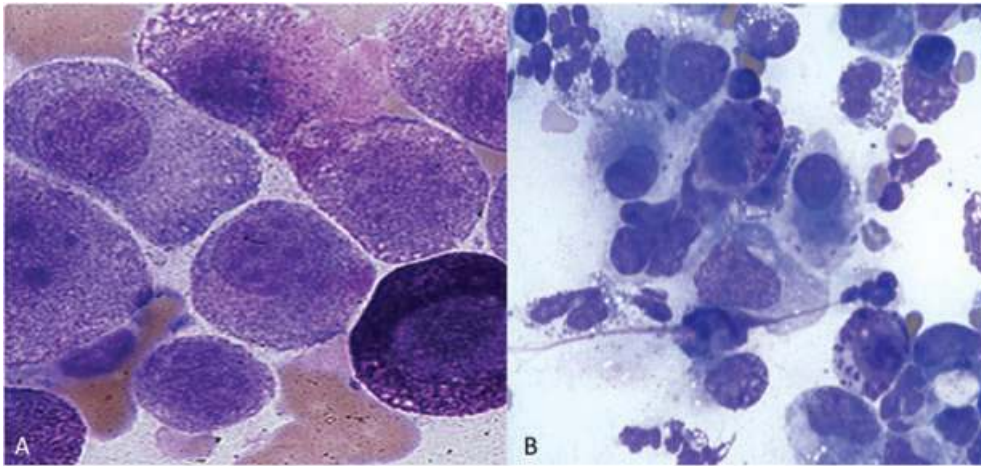
will benefit from a fine needle aspirate (FNA) for diagnosis.

4.3 Diagnostic approach

A cutaneous mass that increases and decreases in size is suggestive of MCT. However, MCT can look like any other skin lesion, and any skin lesion

4.3.1 Fine needle aspirate

FNA cytology gives a diagnosis for 92–96% of MCTs¹⁵ (EBM II). Mast cells readily exfoliate and are easily identifiable by metachromatically



Panel 4. The cytological appearance of mast cell tumours. (A) Represents a typical MCT cytology demonstrating metachromatically staining intracytoplasmic granules. Special stains will identify these granules (toluidine blue, pinacyanol, Wright's or Wright-Giemsa stain). Poorly differentiated mast cell tumours may lack these granules (B).

staining intracytoplasmic granules (Panel 4). Special stains will identify these granules (toluidine blue, pinacyanol, Wright's or Wright-Giemsa stain). Poorly differentiated MCT may lack these granules. FNA will give a diagnosis but not a tumour grade, though a cytologist will suspect a high grade tumour if the cells are very pleomorphic. For an accurate grade, histopathology is required. FNA is inexpensive, can be performed with the animal conscious and allows for better planning of surgery (appropriate margins).

4.3.2 Incisional biopsy

Incisional biopsy involves taking a sample of the mass without attempting to remove it completely. This allows planning of the definitive surgical procedure once the mass has been diagnosed and graded by histopathology. When taking the incisional biopsy, avoid areas of obvious inflammation or necrosis and place the incision so the entire biopsy tract can be resected at definitive surgery. Drawbacks to incisional biopsies compared to FNA are the risk of wound breakdown and the increased cost.

4.3.3 Excisional biopsy

Excisional biopsy is the removal of the mass for histopathological evaluation. If you have an FNA diagnosis of MCT and the tumour is in a site where wide surgical excision can be performed,

then excisional biopsy is appropriate. In some circumstances, such as difficult surgical sites, this approach does not allow the surgery to be planned properly. Since the first surgery is the best chance of cure (as with fascial planes uninterrupted, and no scar tissue, the macroscopic tumour is easily envisaged) excisional biopsy in these sites could jeopardise the chance of a surgical cure¹⁶ (EBM III).

For the best diagnostic approach, see the algorithms in Figs 1 and 2.

4.4 Staging

Once the diagnosis of MCT has been made, appropriate staging should be carried out. Staging defines the nature and extent of disease. MCTs metastasise to draining lymph node(s), liver, spleen and bone marrow and can give rise to local cutaneous satellite lesions.

Most dogs will have tumours that are unlikely to metastasise, and not every patient requires full staging. However, if an extensive or expensive treatment is planned or a poorly differentiated tumour has been identified, staging is recommended. Full staging should include FNAs of draining lymph nodes and abdominal ultrasound as a minimum.

Up to 24% of normal dogs will have a low number of morphologically normal mast cells identified on cytology in a lymph node¹⁷ (EBM III). Difficulties in interpretation arise when small numbers of

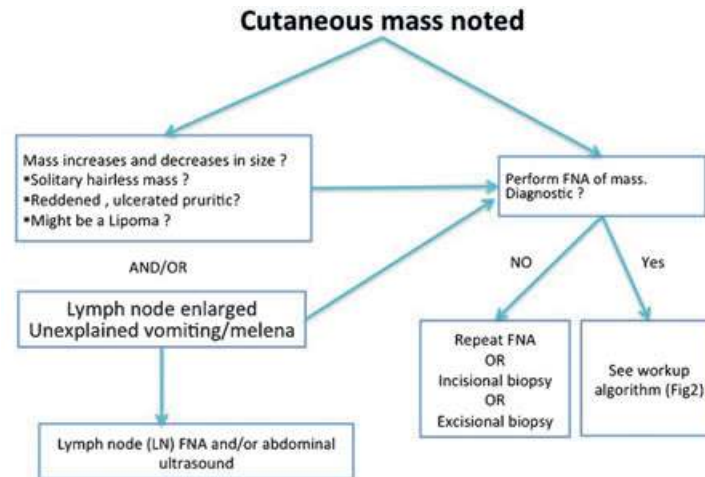


Figure 1. Diagnostic algorithm for a cutaneous mass (Note: cytology is not a substitute for histopathology. Histopathology should be performed after excision of the mass).

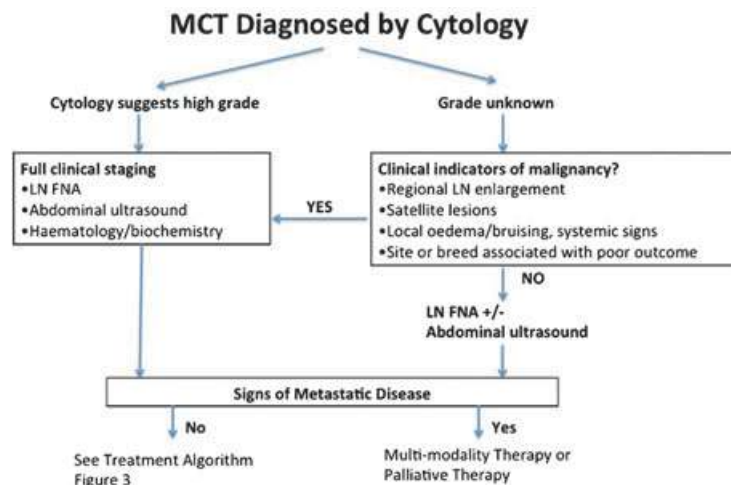


Figure 2. Work-up algorithm following MCT diagnosis based on cytology of FNA.

apparently normal mast cells are seen in FNAs from local or regional nodes, and the cytologist cannot tell if they are reactive or neoplastic. However, as a general rule, if mast cells appear in clusters or sheets, this is suggestive of metastatic disease. Very large numbers of mast cells, abnormal mast cells, or an effacement of normal lymph node architecture on histology, all point to metastatic disease. In recent years the value of examining buffy coat smears in dogs has been questioned¹⁸ (EBM I). Most oncologists agree that buffy coat examination in the dog has limited value in cases of mast cell disease. However, this is still appropriate for cats with certain presentations of mast cell disease.

For patients with nodal metastasis, full staging is required including abdominal ultrasound and eventually bone marrow aspiration and lung radiographs. In these cases, abdominal ultrasound should be accompanied by spleen and liver aspiration whatever their sonographic features (EBM III).^{19,20}

4.5 Prognosis

The behaviour and progression of MCT is highly variable. However, the histological grade is the most important single prognostic factor for MCT.

Table 1. Histological criteria for grade of mast cell tumours (Patnaik *et al.*²¹)

Grade	Histological criteria
1 Well differentiated	Monomorphic round cells with distinct cytoplasm, medium-sized intracytoplasmic granules, no mitotic figures noted. Compact groups or rows of neoplastic cells <i>confined to dermis</i> .
2 Intermediately differentiated	Some pleomorphic cells round to ovoid in shape. Some cells having less distinct cytoplasm with large and hyperchromatic intracytoplasmic granules, but others have distinct cytoplasm with fine granules. Areas of oedema or necrosis are noted. Mitotic figures are 0–2 per high power field. Tumour <i>infiltrating lower dermis/subcutaneous tissue</i> .
3 Poorly differentiated	Dense sheets of pleomorphic cells with indistinct cytoplasm with fine or not obvious intracytoplasmic granules. Mitotic figures 3–6 per high power field. Oedema, haemorrhage, necrosis and ulceration common. Tumour <i>infiltrating lower dermis/subcutaneous tissue</i> .

4.5.1 Histopathology

The Patnaik system is most widely used for cutaneous tumours²¹ (EBM III), and differentiates MCTs into grade I (well differentiated), II (intermediately differentiated) or III (poorly differentiated) tumours (Table 1). Most grade I MCTs are benign, develop slowly and persist for years without increasing in size. Less than 10% of grade I MCT metastasise, and grade I tumours in general are unlikely to cause death of the patient. Grade III tumours show aggressive growth and have a high recurrence potential. More than 80% of grade III tumours metastasise and frequently cause death²² (EBM IV). The prognosis for grade II tumours is variable. Many can be cured by local surgery and only 5–22% of grade II tumours metastasise. However, grade II tumours may cause death in 17–56% of cases due to local treatment failure or metastatic disease. Indicators of prognosis for grade II MCTs would allow the selection of patients with tumours requiring adjunctive therapy.

In addition to the unpredictable behaviour of grade II tumours, histopathological grading is subjective, resulting in grading variation between pathologists. Several studies, including a recent study in 95 dogs, showed that concordance among pathologists was 75% for the diagnosis of grade III MCT and less than 64% for the diagnosis of grade I and II^{23,24} (EBM II). The World Health Organization (WHO) clinical staging system for canine MCT does not correlate clearly with prognosis, so it is not used in a clinical setting^{4,11,25} (EBM III). To improve concordance between pathologists, a two-tier histologic grading system

has recently been suggested²⁴ (EBM II). In this system, the diagnosis of high-grade MCTs is based on the presence of any one of the following criteria:

- (1) At least 7 mitotic figures in 10 high-power fields (hpf)
- (2) At least 3 multinucleated (3 or more nuclei) cells in 10 hpf
- (3) At least 3 bizarre nuclei in 10 hpf
- (4) Karyomegaly (i.e. nuclear diameters of at least 10% of neoplastic cells vary by at least two-fold).

All other tumours are considered low grade. According to the novel grading system, high-grade MCTs were significantly associated with shorter time to metastasis or new tumour development, and with shorter survival time. The median survival time was less than 4 months for high-grade MCTs, but more than 2 years for low-grade MCTs.

Currently, the Patnaik system is still the most widely used grading system for MCT in the dog. However, the two-tier system described by Kiupel may become more widely adopted by pathologists.

4.5.2 Lymph node pathology

Confirmed lymph node metastasis carries a poor prognosis¹¹ (EBM III), but interpretation of nodal involvement is challenging^{26,27} (EBM III).

4.5.3 Anatomic location

MCTs that develop in mucocutaneous junctions and in the inguinal region have historically been reported to be more malignant regardless of histological grade, but this is controversial^{28,29}

(EBM III). The poorer prognosis in these sites may also be due to the difficulty of performing adequate surgery in these locations.

Tumours involving the viscera, intestine or bone marrow usually carry a poor prognosis^{30–33} (EBM III/IV).

4.5.4 Clinical features

The clinical signs of aggressive behaviour (see section *Clinical behaviour*) are usually associated with poor prognosis.

4.5.5 Treatment failure

Recurrence of MCT after surgical removal has been associated with a more guarded prognosis⁸ (EBM III).

4.5.6 c-Kit expression

The RTK c-Kit is dysregulated in 15–40% of canine MCT, usually due to mutations in the *c-Kit* gene. This dysregulation is associated with a poor clinical outcome, increased risk of metastasis and local recurrence and a higher tumour proliferation index^{34,35} (EBM III/IV).

4.5.7 Proliferation markers

Markers of cell proliferation can predict prognosis and response to therapy, and may be less subjective than other prognostic indicators (see Table 2).

4.5.7.1 Mitotic index. The mitotic index (MI) is the number of mitoses per 10 high power fields, determined by standard histopathology and should be provided in every histopathology report.

In a study by Romansik *et al.*³⁶ (EBM III) median survival for dogs with a tumour having a MI of 5 or less was 70 months, compared to 2 months where the MI was greater than 5, irrespective of grade. Early work also showed that patients with tumours with a MI of 10 or more had a survival time of only 11 weeks³⁷ (EBM III). More recently, a cut-off value for MI of 7 rather than 5 has been proposed³⁸ (EBM III). The impact of MI on the likelihood of recurrence was unclear, but Kiupel *et al.*²⁴ (EBM II), showed the importance of MI in predicting likely recurrence in his the two-tier classification system (described above).

4.5.7.2 Ki-67 protein. The Ki-67 protein is a marker for proliferation, expressed during the cell cycle. It can be detected by immunohistochemistry.

Ki-67 expression is significantly associated with MCT prognosis, independent of tumour grade^{39,40} (EBM III). In the Scase study,⁴⁰ Cox regression models indicated that the Ki-67 score and mean argyrophilic nucleolar organizing regions (AgNOR) score were significantly associated with Patnaik grade and survival time. A binary Ki-67 variable (cut-off point Ki-67 score = 1.8) was a significant predictor of survival for dogs with grade II MCT. The estimated 1-, 2- and 3-year survival

Table 2. Cell proliferation markers with a prognostic value in cutaneous mast cell tumours in dogs

Parameter	Significance	Comment	References
Mitotic index (MI)	> 5 prognostic for reduced survival independent of grade. > 7 predictive for recurrence.	Useful test that can be carried out on routine histological sections. Some recommend 7 as cut off, rather than 5.	24, 36–38
Ki-67	High Ki-67 expression is associated with increased mortality, recurrence and metastasis. Prognostic factor independent of histological grade.	Useful if available as proven independent of grade.	39–41
Argyrophilic nucleolar organiser regions (AgNORs)	Higher AgNOR counts associated with increased likelihood of death, recurrence and metastasis.	Not a prognostic indicator independent of histological grade, but may support decision making for grade II tumours.	40, 42
Proliferating cell nuclear antigen (PCNA)	Increased PCNA expression associated with increased mortality. Not consistently with increased risk of recurrence or metastasis.	Not a prognostic indicator without histological grade. Not predictive of survival.	39, 40, 42

probabilities for dogs with grade II MCT and Ki-67 scores less than 1.8 were 0.92, 0.86 and 0.77, respectively. The corresponding survival probabilities for dogs with grade II MCTs and Ki-67 scores higher than 1.8 were 0.43, 0.21 and 0.21, respectively. Higher Ki-67 index values indicate a more proliferative tumour (>1.8) and, for dogs with a solitary cutaneous MCT, may be a useful prognostic parameter, particularly in dogs with grade II tumours when used alongside the Patnaik grading system⁴¹ (EBM III).

4.5.7.3 AgNOR proteins. AgNOR proteins are argyrophilic nucleolar organizing region-associated proteins that bind silver molecules, and can be visualized using a silver-based histochemical stain. The number of AgNOR dots per neoplastic nucleus is inversely proportional to the doubling time. AgNOR counts are associated with survival times, but cannot predict clinical behaviour independent of histological grade^{40,42} (EBM III). However, higher AgNOR counts (with a cut-off value of 2.25) were indicative of MCT with a higher probability of metastasizing, with a lower AgNOR count corresponding to a significantly longer survival period. Cox regression models indicated that the Ki-67 score (hazard ratio, 1.92; $P < 0.001$) and mean AgNOR score (hazard ratio, 2.57; $P < 0.001$) were significantly associated with Patnaik grade and survival time. This study shows that both mean AgNOR score and Ki-67 score are prognostic markers for canine MCTs.

4.5.7.4 Proliferating cell nuclear antigen. The proliferating cell nuclear antigen (PCNA) is a protein required for DNA synthesis. Its expression is associated with cell proliferation.

grade^{39,42} and is not predictive of survival time⁴⁰ (EBM III).

4.6 Subcutaneous MCT in dogs

Until recently there was limited information about prognostic assays used on MCT that arise in the subcutis. Thompson *et al.*⁴³ (EBM III) have described the utility of KIT immunohistochemical labelling pattern, *c-Kit* mutational status (presence of internal tandem duplications in exon 11), and proliferation markers – including MI, Ki67 and AgNOR – as independent prognostic markers for local recurrence and/or metastasis in canine subcutaneous MCT. Sixty subcutaneous MCT in 24 dogs with local recurrence and 12 dogs with metastasis were compared to dogs matched by breed, age and sex with subcutaneous MCT that did not experience these events. MI, Ki67, the combination of Ki67 and AgNOR and KIT cellular localization pattern were significantly associated with local recurrence and metastasis, thereby demonstrating their prognostic value as a panel for subcutaneous MCT. No internal tandem duplication mutations were detected in exon 11 of *c-Kit* in any tumours in this study, but numbers were low.

4.7 Treatment

The treatment options for MCT depend on the clinical features, clinical stage and grade. The main questions should be:

- (1) Is surgical excision possible?
- (2) Is local therapy sufficient or is systemic therapy also required?

A treatment algorithm is shown in Fig 3A and B. In addition, a guide for practitioners to identify when to refer cases to a specialist is given in Box 1.

Box 1: When to refer an MCT patient to a specialist

- (1) Challenging surgical site
- (2) Case suitable for radiotherapy
- (3) Case suitable for chemotherapy/TKI treatment.

PCNA expression is significantly higher in recurrent versus nonrecurrent tumours and in metastatic versus nonmetastatic tumours. However, it is not independent of histological

4.7.1 Surgery

Surgery is the treatment of choice in localized, nonmetastatic canine MCTs (EBM III/IV).^{44,45}

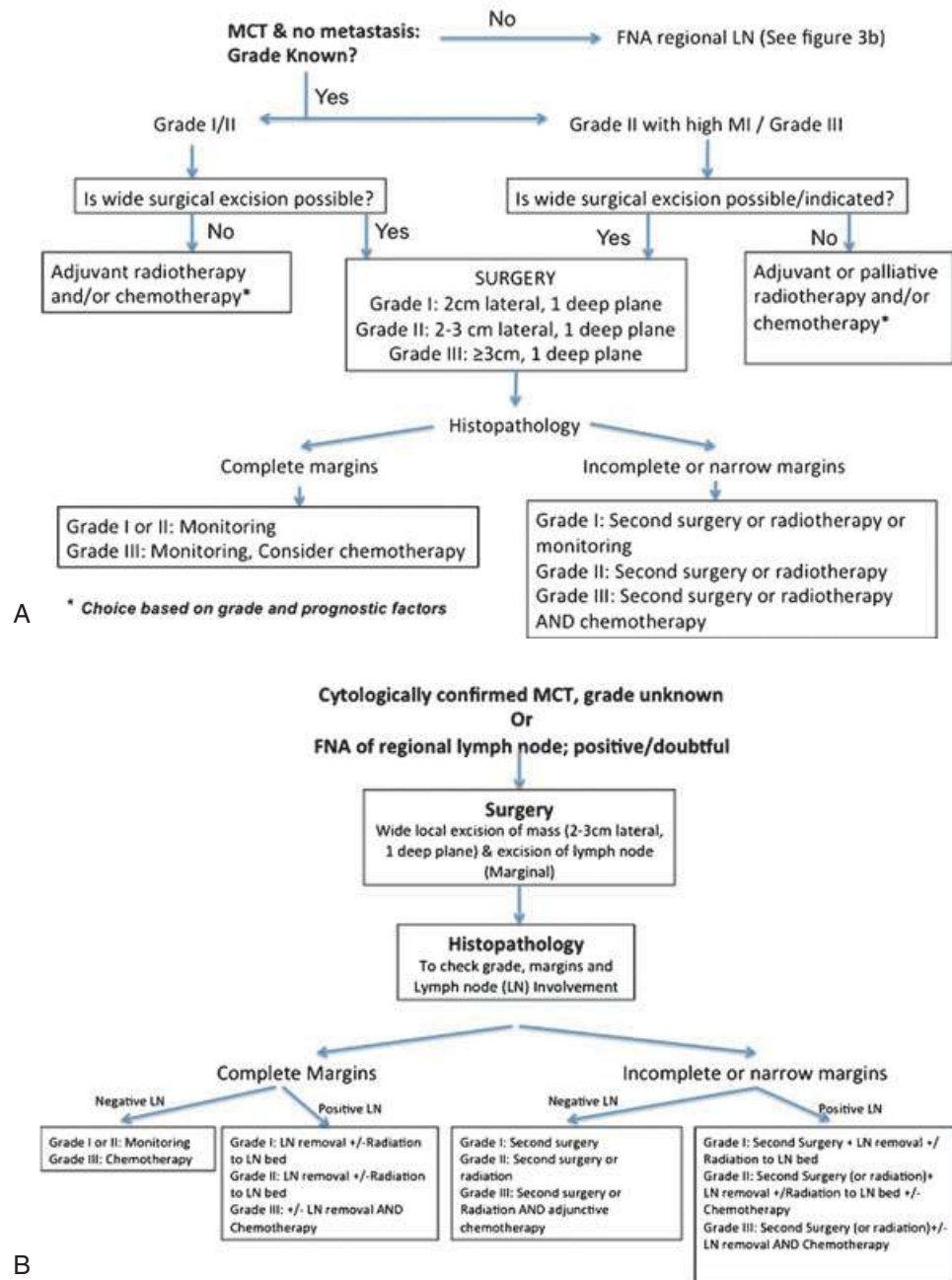
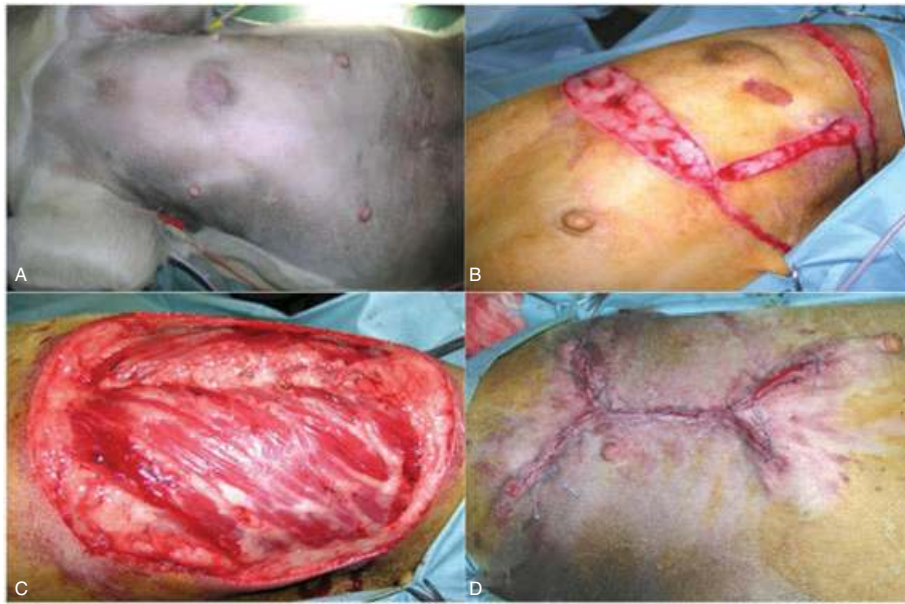

Figure 3. (A) Treatment algorithm for a cutaneous mass without signs of metastasis. If more than one treatment option is given, they are listed in order of preference. (B) Treatment algorithm for a cutaneous mass if no grade is available and FNA suggests involvement of the regional lymph node. If more than one treatment option is given, they are listed in order of preference.

MCT may degranulate in response to surgical manipulation. Particularly where there is bulky disease, perioperative administration of H1- and H2-blockers is recommended to reduce the risk of local and systemic effects⁸ (EBM IV).

4.7.1.1 Surgical margins. Historically (since the 1960s), a 3-cm margin in all directions has been recommended for excision of MCTs, while the deep margin should include at least one fascial plane (EBM IV)^{4,8,44} (Panel 5).



Panel 5. Simple excision of a grade II MCT (A) demonstrating wide (2–3 cm) surgical margins (B, C) and reconstruction of the wound (D).

More recent studies show that for most grade I and II MCTs, a lateral margin of 2 cm and a deep margin of one fascial plane is sufficient^{10,46,47} (all EBM III). In a more recent retrospective study, excision of both grade I and II MCTs (of between 2 and 31 mm) with a lateral margin of at least 1 cm and a deep margin of at least 4 mm did not result in recurrence⁴⁸ (EBM III). Therefore, it is reasonable to conclude that a less aggressive resection does not result in a higher recurrence rate for smaller low-grade tumours, and facilitates wound reconstruction. The deep margin should include the panniculus muscle (if present), the underlying fascia or, in its absence, the superficial layer of the musculature^{46,47,49} (all EBM III). Where there are concerns regarding margins, biopsies should also be submitted from the tumour bed.

This '2cm/one fascial plane' recommendation has not been evaluated for large tumours greater than 4 cm in diameter. In addition, higher-grade tumours are more locally invasive and the rule cannot be recommended for these tumours.

Grade III tumours should be excised with a lateral margin of at least 3 cm plus the deep fascial plane. However, as the risk of local recurrence and metastasis is high, multimodal treatment is preferred⁸ (EBM IV).

4.7.1.2 Tumours in difficult locations. Tumour location may influence the feasibility of wide local excision. Most often, it is the deep margin that is challenging, in areas such as the distal limbs or face. Even obtaining adequate lateral margins may be challenging in areas of limited skin, particularly the limbs distal to mid antebrachium or hock, and reconstructive surgery is often required (e.g. free grafts, axial pattern flaps). It should also be noted, however, that Brocks *et al.*³⁸ (EBM I) reported that a 0.5 cm or less excisional surgical margin for MCT on distal limbs gave a 2-year recurrence-free rate of 93%. The goal of this study was to evaluate the ability of hypotonic water to reduce the recurrence rate in incompletely resected MCT, in particular those in difficult locations where 0.5 cm margins could not be achieved. Treatment with hypotonic water did not prevent recurrence, and prognosis was determined by the histological grade. However, based on the results of this study, a 0.5 cm resection cannot be recommended as local infiltration with hypotonic water is a confounding variable. It is the authors' opinion that further studies are necessary before a surgical excision less than 1 cm may be recommended, even for apparently low grade canine MCT.

Neoadjuvant chemotherapy or prednisolone therapy can be used to make the tumour more amenable to surgery⁵⁰ (EBM III). Where complete excision remains impossible, a conservative (cytoreductive or marginal) resection followed by adjuvant radiotherapy is usually preferred over a radical surgical procedure²² (EBM IV) and (EBM III).^{51–54} Small molecule tyrosine kinase inhibitors (TKIs) have also shown efficacy in nonresectable MCT (toceranib and masitinib)^a.

The use of adjuvant radiotherapy following reconstructive surgery may lead to complications (EBM III⁵⁵). Chemotherapy has also been suggested as an alternative to radiation for incompletely excised canine cutaneous grade II MCTs^{56,57} (EBM III).

4.7.1.3 Histological examination of surgical margins. The histological evaluation of margins can be defined as:

- (1) *Complete resection* (no tumour cells within 1 mm of the surgical margin)
- (2) *Complete but close* (mast cells within 1 mm of the surgical margin), or
- (3) *Incomplete* (mast cells at the surgical margin)⁵⁰ (EBM III).

The presence of sheets or clusters of mast cells with features of malignancy at the resection margins should be interpreted as incomplete excision. However, if there are sparse mast cells on the periphery of the excised tissue, it can be difficult to tell if these are tumour cells or just physiologic mast cells attracted by chemotaxis^{33,41,47,49,58} (all EBM III).

Many apparently incompletely excised solitary grade II MCT do not recur^{10,45–47,49,55,59} (all EBM III), suggesting that some of the observed mast cells on the periphery may not be neoplastic. In addition, even after apparently complete surgical resection local recurrence may occur in 5–23% of the cases^{10,15,55,59} (all EBM III). However, the recurrence rate in cases with nonclean margins is significantly increased compared to clean resections⁶⁰ (EBM III).

Treatment recommendations depend on the margins found at histopathology (see Fig 3A and B):

- (1) For grade I and II tumours with histologically complete excision and 'clean' tumour bed biopsies, no adjuvant therapy is required, but monitoring is recommended. In case of pre-existing metastatic disease, adjunctive treatment is required.
- (2) For grade I and most grade II tumours, where incomplete margins are reported but without gross disease and where the wound has healed uneventfully, the preferred option is to perform an 'en bloc' excision of the scar with 2 cm margins. Alternatively follow-up radiotherapy can be performed, or the site can be monitored. However, if margins are incomplete/narrow and there is macroscopic residual disease, recurrence, or metastasis, a 'wait and see' approach is never appropriate. The situation with microscopic disease alone is a difficult decision as only one-third of grade II tumours in this category are reported not to grow back⁵⁵ (EBM III).
- (3) Surgery in dogs with nodal metastases. In grade I and II MCTs with likely or confirmed local lymph node involvement, the treatment of choice is combined surgery and radiotherapy. Good outcomes with a median disease-free interval of 40.6 months have been found for combined therapy with surgery and irradiation⁵⁴ (EBM III) and (EBM IV).²² Chemotherapy should also be considered in these patients⁵⁶ (EBM III).

4.7.1.4 Surgery in dogs with multiple MCT. In multiple MCTs, all tumours amenable to surgery should be excised. The prognosis for multiple MCTs is not generally worse than that for solitary tumours^{6,11} (EBM III).

4.7.2 Radiotherapy

Complete surgical excision should be considered the best local treatment for MCT, and radiation therapy should be restricted to cases where surgery cannot achieve local control. If a second surgery with wider margins around the surgical scar can be

^aPalladia® – Summary of product characteristics EMA 2009.

carried out, this may provide a complete excision, and this option should be considered. However, radiotherapy can also be used to treat local/regional nodal metastases.

Radiotherapy is generally avoided as a sole therapy where there is bulky disease due to the risk of radiation-induced mast cell granulation and serious systemic effects. Larger tumour volume is also associated with shorter disease-free interval⁵³ (EBM III). Larger tumours are more likely to contain radiation-resistant tumour cell clones and areas of radio-resistant tissue due to micro-environmental factors such as hypoxia, and are also more difficult to irradiate.

Radiotherapy is most often used as a postoperative adjunctive therapy after incomplete excision. Best results are achieved where radiation is planned or considered prior to surgery, rather than as an afterthought after an inadequate surgery. In order to maximize the chances of a good outcome, accurate recording of the presurgical tumour is required (photographs or sketches, dimensions), to ensure there is not a 'geographical miss'. A 'miss' occurs when tissue that was originally within the planned treatment margins of the tumour is not included in the radiotherapy treatment field, making recurrence more likely. Ideally, metal surgical clips should be placed at the surgical margins: these can be visualized by radiographs taken using the radiotherapy machine during treatment (portal imaging). Clips are especially useful on the trunk, body wall and proximal limbs where there may be substantial post surgical tissue migration.

The use of advancement flaps and grafting techniques may increase the field size for treatment and result in a delay in starting radiation therapy because of delayed wound healing or wound breakdown. A conservative surgery with primary closure may be preferable when postoperative radiation therapy is planned. In particular, consideration should be given to simpler techniques when a flap or graft procedure will only allow an increase in lateral margins, but does not alter deep margins.

On the limbs, a strip of skin must be excluded from the radiation field to prevent the development of lymphoedema due to damage to the lymphatic drainage. This means the whole circumference of the limb cannot be irradiated, limiting margins.

Oblique and transverse incisions should be avoided. Most centres offering radiotherapy will be able to irradiate tumours of the limbs and extremities. For tumours of the thoracic or abdominal wall, electron or orthovoltage radiation may be required.

The prognosis for canine MCTs treated with surgery and radiation is generally good, but published data are difficult to interpret in view of the relatively low rate of recurrence reported with surgery alone, even in case of incomplete histological margins⁴⁹ (EBM III).

Adjuvant radiation therapy for intermediate grade MCTs results in 1- to 2-year disease-free intervals in 81–95% of cases^{51,52,54} (all EBM III). Disease-free intervals of 40 months have also been reported for dogs with grade I/II tumours with regional lymph node metastases treated with surgery and radiation⁶⁰ (EBM III). Several different fractionation regimes are reported and the ideal protocol is unknown. However, where definitive protocols are used, higher recurrence rates are reported at less than 40 Gy total dose⁵³ (EBM III). There have been no randomized trials comparing hypofractionated and definitive protocols.

Prednisolone therapy is often given to patients before, during and for several weeks after radiotherapy to reduce the severity of radiation-induced mast cell degranulation and consequent adverse effects. Similarly, H1-blockers such as chlorpheniramine and H2-blockers such as cimetidine or ranitidine are also administered to minimize the systemic effects of mast cell degranulation.

4.7.3 Chemotherapy

Chemotherapy can be used in dogs in three ways:

- (1) Where systemic rather than loco-regional therapy is required, to treat, delay or prevent disseminated metastases, in high-grade tumours.
- (2) In a neo-adjunctive setting, prior to surgery or radiotherapy, to reduce tumour burden (down-stage disease) and improve the likelihood of achieving complete excision, or to make it easier and safer to irradiate the mass. However, there are no studies properly evaluating efficacy of chemotherapy in this setting.

Prednisolone alone is also used in this way^{50,61} (EBM III).

- (3) To treat residual microscopic disease where further surgery is not possible and radiation therapy is not available. Outcomes in this setting have only been reported in 20 cases, where 18 dogs did not have local recurrence after 1 year⁶² (EBM III). These data should be interpreted with care as many grade II tumours were included, which have a relatively low recurrence rate with incomplete margins.

Systemic treatment with chemotherapy is most appropriate for tumours with a high risk of metastases: grade III tumours, tumours where the pathologist suggests grade II/III features and grade II tumours with risk factors for reduced survival and/or metastases such as high proliferation marker values.

Chemotherapy is most often used to delay or prevent metastatic disease (in addition to surgical treatment of the primary site), or to delay progression of existing metastatic disease, but efficacy studies are lacking. In one study, 61 dogs with either grade III or II tumours thought to be at high risk of metastasis were treated with prednisone and vinblastine (following excision with or without radiation therapy). All patients were alive 3 years later, with a disease-free interval of 1305 days⁵⁶ (EBM III). This compares favourably with historical data on survival for patients with grade III tumours, treated with surgery alone, where only 6–27% of patients were alive after 1 year^{12,21,37} (all EBM III).

4.7.3.1 Drugs and protocols. The most common chemotherapy protocols used to treat canine MCT are summarized in Table 3. First-line therapy often consists of vinblastine and prednisolone, and second-line therapy of lomustine, but protocols alternating vinblastine and lomustine are also commonly used.

There is limited data to support the use of other chemotherapeutic agents in the treatment of canine MCTs. Good response rates have been reported with combined vinblastine, cyclophosphamide (CYC) and prednisolone, but the duration of response was not better than other protocols, and the additional

potential toxicity without proven survival advantage means this protocol has not become established⁶⁹ (EBM III). Chlorambucil and prednisolone resulted in a measurable response in 8 of 21 (38%) cases, with a median progression-free interval for responders of 533 days and a median survival time of 533 days⁷⁰ (EBM III). Single agent hydroxyurea resulted in a measurable response in 13 of 46 (28%) dogs for a median of 60 days⁷¹ (EBM III).

There are no randomized trials comparing the survival advantage of different protocols in patients with MCT with high risk of metastases.

Prednisolone is active against canine MCT, but when used alone it has a low response rate, with only 20% of patients with measurable disease achieving a complete or partial response (5 of 25 patients responded, with survival times for those that died due to progressive disease of 3, 5 and 6 months for those with PR, and 22 months for one dog that achieved CR⁷² (EBM III)).

4.7.3.2 Toxicity. The choice of a chemotherapeutic drug should take account of its potential toxic effect.

Vinblastine is a severe perivascular irritant and must be given via a cleanly placed, first-stick intravenous catheter. It is also potentially myelosuppressive and haematology must be checked prior to each dose. The recommendation is that, in a general practice situation, drug should not be given if the neutrophil count is less than $3 \times 10^9 \text{ L}^{-1}$ or the platelet count is subnormal. In some circumstances, oncologists may elect to treat patients with lower counts. Myelosuppression is mainly seen in patients receiving weekly treatments (at the start of chemotherapy) and the interval may need to be extended in some patients. GI toxicity is generally mild.

Lomustine can be very severely myelosuppressive. Myelosuppression may be delayed, and recovery slower than with other drugs. Idiosyncratic severe thrombocytopenia can occur. Haematology must be checked prior to each dose, and the drug should not be given if there are cytopaenias as above. Lomustine is also hepatotoxic, and it is unclear if this is idiosyncratic or related to total dose received. Monitoring of ALT is recommended. There are no established guidelines, but some oncologists suggest treatment should

Table 3. Commonly used chemotherapy protocols for canine mast cell tumours (after Blackwood, BSAVA Manual of Oncology, 3rd edition⁶³)

Drug	Published total response rate (sum of complete and partial responses for measurable disease)	Protocol	Comment/toxicity	References (EBM grade)
Vinblastine and prednisolone	47.00%	Vinblastine 2 mg m ⁻² IV weekly for 4 weeks then fortnightly for four further treatments. Prednisolone 2 mg kg ⁻¹ PO once daily for 1 week, then 1 mg kg ⁻¹ daily for 2 weeks, then 1 mg kg ⁻¹ every other day.	6–20% toxicity: myelosuppression and GI toxicity. Can roll vinblastine out to 6 months. Dose escalation of vinblastine may be possible in some cases.	(EBM III) ^{56,64,65}
Lomustine	44.00%	70 mg m ⁻² PO q21d for four cycles.	Lomustine is associated with myelosuppression, GI and hepatotoxicity. Toxicity of longer term monotherapy unknown if lomustine continued. Lomustine often used as rescue therapy after vinblastine and prednisolone.	(EBM III) ⁶⁶
Vinblastine/lomustine (alternating vinblastine/lomustine, one treatment q14d)	57%	Vinblastine 2 mg m ⁻² IV week 1 then every fourth week. Lomustine 60 mg m ⁻² PO week 3 then every fourth week.	Planned protocol 4–6 cycles Toxicity in 54% of cases, mainly myelosuppression.	(EBM III) ⁶⁷
Vinblastine/lomustine and prednisolone (alternating vinblastine/lomustine, one treatment q14d)	Not published (reported in opinionated review)	Vinblastine 2 mg m ⁻² IV week 1 then every fourth week. Lomustine 70 mg m ⁻² PO week 3 then every fourth week. Prednisolone 0.5 mg kg ⁻¹ PO daily.	Protocol continues for 6 months.	(EBM IV) ²²
Vinblastine/lomustine and prednisolone (alternating vinblastine/lomustine, one treatment q14d)	65%	Lomustine 70 mg m ⁻² PO week 1 then every fourth week. Vinblastine 3.5 mg m ⁻² IV week 3 then every fourth week. Prednisolone 2 mg l ^k -1 PO daily for first 2 weeks then 1 mg kg ⁻¹ daily until week 24 then tapered over 4 weeks.	Of 48 dogs, 13 required lomustine dose reduction and 17 required vinblastine dose reduction, due to significant myelosuppression. 33% developed severe neutropenia, 28% hepatotoxicity. CARE advised in general practice. 24-week protocol.	(EBM III) ⁶⁸

be stopped if ALT exceeds 250 IU L⁻¹, or after a maximum of six doses or 6 months treatment⁵⁷ (EBM IV). One study reported fatality in 2 of 12 dogs with MCT, due to hepatotoxicity⁵⁷ (EBM III). However, co-administration of denamarin with lomustine reduces drug-induced increases in liver

enzymes, and is thought to be hepatoprotective⁷³ (EBM II/III).

4.7.4 Tyrosine kinase inhibitors

RTKs are an important group of cell surface receptors that trigger cellular activation resulting

in cell proliferation, differentiation and survival when stimulated by their cognate ligands (see Box 2 with Figs 4 and 5). Normal kinase function is critical to cell growth and differentiation, and dysfunction of several RTKs has been characterized in a variety of cancers. RTKs have also been implicated in new blood vessel formation in tumours (angiogenesis) and the process of metastasis.

to maintain angiogenesis, promote metastasis and support the tumour niche environment.

Specific small-molecule TKIs are able to block the activity of receptors by competitive inhibition of ATP binding (Fig 5). Recently, two RTKIs were approved by the European Medicines Agency (EMA) for use in MCT in dogs:

Box 2: Receptor tyrosine kinases – Their role and inhibition

Tumours cannot grow more than a few millimetres without a blood supply. So-called endothelial precursors are induced to grow into new blood vessels (angiogenesis), through stimulation of receptors on their cell surface. These receptors, called receptor tyrosine kinase or RTKs, bind growth factors. RTKs are activated following binding of the ligand to the extracellular domain of two receptor monomers. This brings them together, and produces a receptor dimer, which activates protein kinase activity. As a result of this activation, downstream signalling pathways within the cell are activated (Fig 4). Transmission of signals to the nucleus leads to altered expression of a wide range of genes involved in cell proliferation, survival and differentiation, allowing tumour growth and angiogenesis.

The activation steps depend on phosphorylation, which require ATP binding. This ATP binding is often the target for inhibitory drugs (Fig 5).

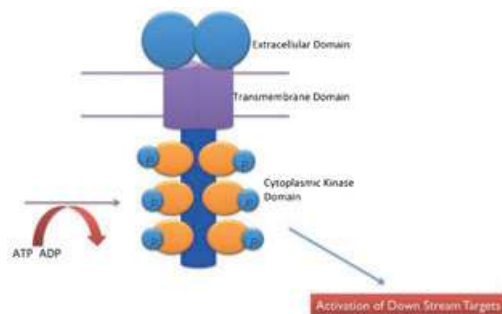


Figure 4. The structure of a receptor tyrosine kinase.

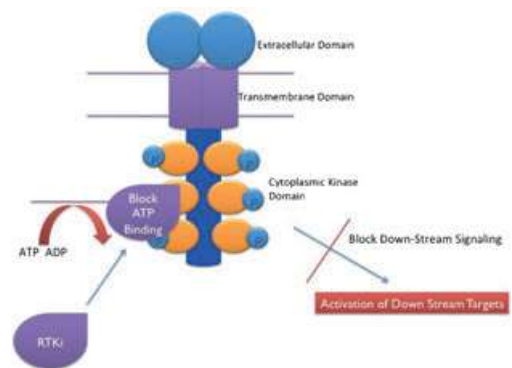


Figure 5. Activity of RTK inhibition.

RTKs are dysregulated in certain cancers. Dysregulation may be due to overexpression, mutation, chromosomal translocation or autocrine signalling. In these cases, growth factor is no longer needed. One such RTK is called KIT, encoded by the *c-Kit* gene. Recent studies have found that mutations in *c-Kit* may be associated with MCT development in dogs, particularly higher grade tumours: mutations are found in about 30% of canine grade II and III MCT.^{34,74} These are gain-of-function mutations, causing constitutive activation of the KIT receptor without the requirement for ligand binding. Inhibition of the RTK will block ATP binding and the cascade of biochemical reactions (downstream signalling), leading to a reduced proliferation, migration, apoptosis and angiogenesis, depending on the RTK targeted (Fig 5).

The normal activity of RTKs – such as the platelet-derived growth factor receptor (PDGFR) or the vascular endothelial growth factor receptor (VEGFR) – may be utilized by the tumour stroma

Both were developed to target KIT^{75,76} (EBM III). Toleranib also targets VEGFR2 and PDGFR, RTKs that play an important role in tumour angiogenesis and metastasis⁴ (EBM IV).

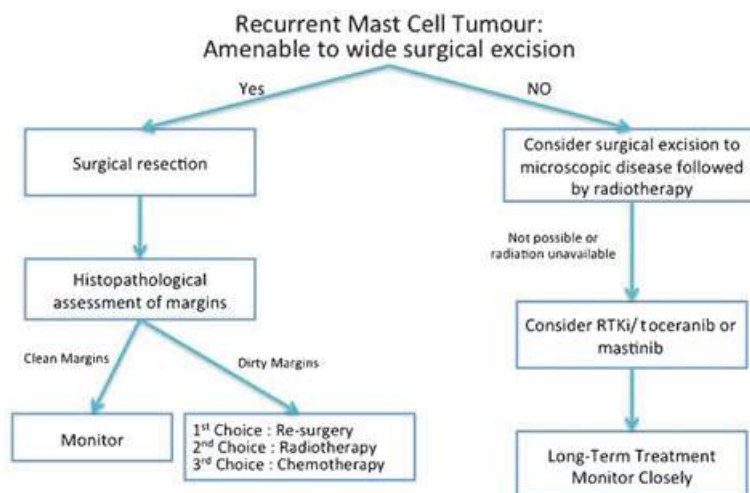


Figure 6. Algorithm for TKI use in canine mast cell tumours. If consideration is being given to RTKI therapy, then it is strongly recommended that you discuss the case with a specialist oncologist and follow close monitoring for potential adverse reactions.

- (1) Toleranib phosphate (Palladia[®], Pfizer Animal Health), approved for use in recurrent, nonresectable grade II/III MCT^a.
- (2) Masitinib (Masivet[®], AB Science), approved for use in nonresectable grade II/III MCT with established *c-Kit* mutation, which should be confirmed before treatment^b.

Both drugs have demonstrated efficacy as single agents in prospective clinical trials in dogs (EBM I)^{77,78} and (EBM II/III).⁷⁹

The efficacy of toceranib was demonstrated in dogs with advanced recurrent cutaneous grade II/III MCT with or without lymph node involvement⁷⁷ (EBM I). Treatment with toceranib provided a statistically significant improvement in the objective response rate (ORR) versus placebo in the blinded phase. The ORR for all dogs receiving toceranib was 42.8% and the biological response rate including dogs with stable disease for more than 10 weeks was 59% (EBM I)^c. The presence of a *c-Kit* mutation and the absence of regional lymph node metastasis, but not the tumour grade, were significantly associated with

a higher objective response. Dogs with grade II tumours and dogs without regional lymph node metastasis had a longer time to tumour progression (TTP). There was no significant association between *c-Kit* mutation status and time to tumour progression or duration of response⁷⁷ (EBM I).

The efficacy of masitinib was studied in dogs with nonresectable or recurrent grade II or III MCT without nodal or visceral metastasis, previously treated or not⁷⁸ (EBM I). Treatment with masitinib significantly prolonged time to tumour progression in all dogs compared with placebo, but this was not significant in dogs with a mutant form of KIT receiving masitinib as second-line or later treatment. Masitinib increased overall survival only in MCT dogs expressing a mutant form of KIT (*c-Kit* positive) and there was no statistically significant difference between masitinib and placebo at the 6-month evaluation⁷⁸ (EBM I).

An additional study showed that masitinib used as a first-line treatment increased 12 and 34 months survival rate in dogs with nonresectable MCT⁷⁹ (EBM II/III). However, current guidelines indicate that RTKIs should not be considered as first-line therapy. Although investigator-led studies are still in progress, an algorithm for current recommended usage is shown in Fig 6.

^aPalladia[®] – Summary of product characteristics EMA 2009.

^bMasivet[®] – Summary of product characteristics EMA 2008.

^cPalladia[®] – Scientific discussion EMA 2009.

RTKIs are a new and exciting class of drugs that give the practitioner a further treatment modality in treating MCT. However, all the potential indications for this class of drugs are not yet known in canine and feline with MCT and other type of cancers and metastasis, especially when inhibition of angiogenesis is involved.

The oral formulation makes this class of drugs easier to administer. However, patients receiving RTKIs should be closely monitored, as they would be for conventional cytotoxic therapy (see Box 3), as adverse drug-specific reactions have been described with both licensed medications. The most commonly reported clinical side effects reported with the use of toceranib included diarrhoea, anorexia, lethargy, vomiting, lameness and weight loss⁷⁷ (EBM I) and Palladia^{®a}. The most common side effects reported with masitinib were diarrhoea, vomiting, oedema and neutropenia, but renal disorders with protein losing nephropathy and haemolytic anaemia have also been described⁷⁸ (EBM I) and Masivet^{®b}.

4.7.4.1 RTKIs combined with conventional chemotherapy drugs. Studies combining RTKs with conventional chemotherapy drugs are currently lacking. However, recently a phase 1 clinical study was conducted to evaluate the safety of combinations vinblastine and toceranib in dogs⁸⁰ (EBM III/IV). In this study, the dose-limiting toxicity for the simultaneous combination was neutropenia and the maximally tolerated doses were:

- (1) Vinblastine (1.6 mg/m² every other week) concurrent with
- (2) Toceranib (3.25 mg/kg PO, every other day).

This represents greater than a 50% reduction in dose-intensity for vinblastine (compared to single-agent use) and as such does not support this combination based on current drug combination paradigms⁸⁰ (EBM III/IV). While a strict adherence to dose paradigms speaks against the combination, evidence of significant activity (71% objective response) and enhanced myelosuppression suggest additive or synergistic activity. A prospective

Box 3: Practicalities of RTKI usage in MCT

RTKIs are currently licensed in Europe for the treatment of recurrent MCT where surgical excision is not possible or appropriate. If consideration is being given to RTKI therapy, then it is strongly recommended that you discuss the case with a specialist oncologist and follow close monitoring for potential side effects.

As a guide:

- (1) These drugs are anti-cancer agents that, like conventional cytotoxic drugs, can cause side effects.
- (2) Side effects reported in the literature are largely grade I/II (mild to moderate) but grade III/IV (severe) can occur in some sensitive patients or where treatment is inappropriate. Side effects are varied but include GI signs (diarrhoea) and effects of the haematopoietic system (neutropaenia). Not every side effect is similar to those seen with conventional cytotoxic drugs. For example muscle cramping is reported with toceranib and protein losing nephropathy with masitinib. Close clinical monitoring is required (especially in the early stages of treatment)
- (3) Complications of therapy can arise and may require treatment holidays or dose reductions. If you are considering using this drug, based on the algorithm in Fig 6, then it is recommended that you discuss the case with a specialist oncologist in referral practice first.
- (4) RTKIs should not be considered as an alternative to surgical resection where this can be performed in practice or by a specialist surgeon.

The beneficial and adverse effects of RTKIs and chemotherapy drugs in combination are currently being investigated.

randomized evaluation comparing this combination with standard single-agent treatments needs to be conducted to interrogate this possibility.

Interestingly, another recent prospective clinical trial in client-owned dogs toceranib phosphate and metronomic dosing of cyclophosphamide were

^aPalladia[®] – Summary of product characteristics EMA 2009.

^bMasivet[®] – Summary of product characteristics EMA 2008.

combined in an attempt to improve tumour control by suppression of regulatory T cells (Treg) and restoration of T cell-mediated immune responses⁸¹ (EBM II/III). Results demonstrated that toceranib significantly decreased the number and percentage of Treg cells in the peripheral blood of dogs with cancer. Dogs receiving toceranib and cyclophosphamide demonstrated a significant increase in serum concentrations of IFN- γ , which was inversely correlated with Treg numbers after 6 weeks of combination treatment. These data support an immunomodulatory function of RTKIs in cancer.

4.7.4.2 RTKIs combined with radiation treatment. Recently, a multicentre prospective trial was conducted to establish the tolerability of using toceranib phosphate in combination with hypofractionated radiotherapy in nonresectable MCT⁸² (EBM III). In this study, toceranib was administered for 1 week before initiating RT, consisting of a total of 24 Gy delivered in three or four fractions. The overall response rate was 76.4%, with 58.8% of dogs achieving a complete response and 17.6% a partial response. The median time to best response was 32 days, and the median progression-free interval was 316 days. The overall median survival time was not reached with a median follow-up of 374 days. These response rates and durations were higher than those reported for toceranib as a single-agent treatment for MCT, but this study included the addition of prednisolone. Predictably, the most common toxicities were related to the GI tract and the liver.

On the basis of the current evidence, the algorithm in Figure 6 can be used to determine the role of RTKIs in the management of MCT. As new evidence emerges, this algorithm may change.

4.7.5 Other treatments

Less established treatments for canine MCTs include local injection of corticosteroids or deionized water, immunotherapy, cryotherapy, hyperthermia and electrochemotherapy.

4.7.5.1 Intralesional corticosteroids. Intralesional corticosteroids have been used in nonresectable

tumours and those that have failed other treatments^{83–85} (all EBM IV). No controlled studies have been performed to compare this with systemic treatment.

4.7.6 Immunotherapy

Immunotherapy has been used in individual cases^{86,87} (EBM IV). Initial response rates similar to single agent vinblastine have been described using a preparation containing human chorionic gonadotropin and bacillus Calmette-Guerin⁸⁸ (EBM III), but a large proportion of dogs were withdrawn prior to completion of the 6-week protocol so follow-up data was limited.

4.7.6.1 Intraregional deionized water. Intraregional deionized water has been recommended as an adjuvant after incomplete resection^{89–93} (all EBM III), but not all trials demonstrate efficacy. A recent randomized study has shown that hypotonic water does not decrease local recurrence or improve survival times in dogs with incompletely excised solitary MCT³⁸ (EBM I).

4.7.6.2 Hyperthermia. Hyperthermia – heating tumour tissue to 40–45 °C – was used in combination with radiotherapy in the 1980s^{94,95} (EBM IV). Additional benefit compared to radiotherapy alone is unproven.

4.7.6.3 Photodynamic therapy. Photodynamic therapy relies on local application of light of certain wavelengths to activate systemically delivered drugs, and has been used in MCT (EBM IV)^{96–100,102}, (EBM III/IV).^{101,102} Responses are reported, but treatment may precipitate degranulation, and is only suitable for relatively small superficial lesions, which are likely to be amenable to surgery.

4.7.6.4 Cryosurgery. Cryosurgery or cryotherapy has been used to treat small (<1 cm) MCT^{16,103,104} (all EBM IV), but may cause mast cell degranulation. The utility of this approach is limited to areas with small tumours where a complete excision is difficult¹⁰³ (EBM IV).

4.7.6.5 Electrochemotherapy. Electrochemotherapy combines the administration of chemotherapeutic drugs (cisplatin or bleomycin) with application of electric pulses to the tumour to increase local uptake of drug (EBM IV)¹⁰⁵, (EBM III).^{106,107} Complete and partial responses have been reported in MCT (EBM III).^{106,107} Local cisplatin and electrochemotherapy has been recently suggested as an alternative to adjuvant radiotherapy for incompletely resected MCT¹⁰⁸ (EBM III). However, there are health and safety considerations and this is therefore not recommended routinely (EBM IV).

4.7.7 Supportive therapy

Supportive care includes medication to counter the effects of histamine release:

- (1) H2 antagonists to treat gastric ulceration: cimetidine (4 mg/kg PO q8h), ranitidine (2 mg/kg PO q12h), famotidine (0.5–1 mg kg⁻¹ PO q12–24h) or the proton pump inhibitor omeprazole (0.5–1 mg kg⁻¹ PO q24h).
- (2) H1 antagonists to decrease the adverse effects of histamine release on peripheral vasculature and wound healing: diphenhydramine (2–4 mg kg⁻¹ PO q12h).

Supportive therapy is particularly important in dogs with GI signs, and where degranulation is anticipated⁸ (EBM IV), but is appropriate in all patients with measurable MCT. The gastro-protective drug sucralfate is recommended in cases with GI signs.

4.8 Quality of life

Quality of life issues may lead to euthanasia in patients with noncurable MCT, due to unresectable or recurrent local disease causing local signs, disseminated tumours causing organ dysfunction or paraneoplastic effects. Acute deterioration and fatality may result from anaphylaxis or gastroduodenal haemorrhage or perforation¹⁰⁹ (EBM IV).

No published studies have been performed to precisely evaluate quality of life of pets with MCT (EBM IV). However, in one study evaluating the efficacy of the RTK inhibitor toceranib phosphate

(Palladia®), Palladia-treated responders scored statistically higher on health-related quality of life versus Palladia-treated nonresponders⁷⁷ (EBM I).

5 Feline mast cells tumours

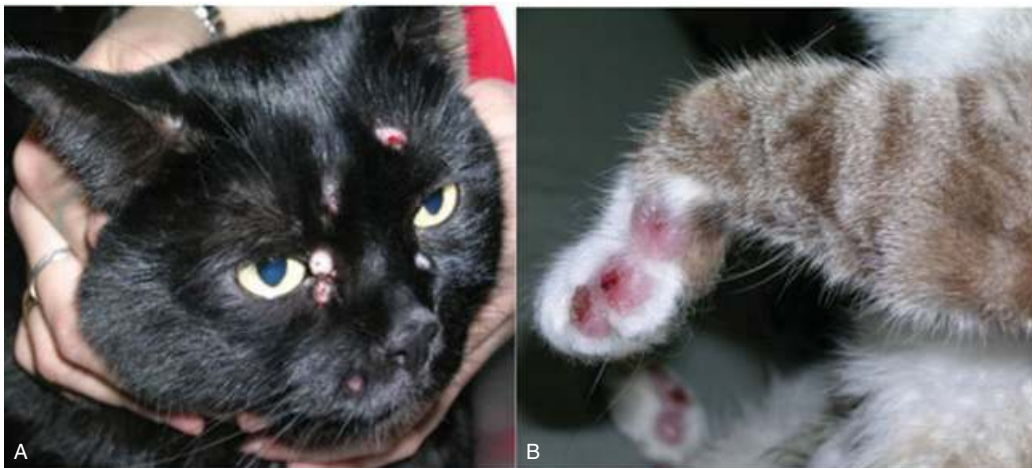MCT are the second most common cutaneous tumours in the cat, accounting for approximately 20% of skin tumours. Two different histological subtypes of MCT exist in the cat: the mastocytic form, similar to MCT in dogs, and the less common atypical form. The 'atypical' form was until recently referred to as the 'histiocytic' form. The mean age at development of the mastocytic form is 10 years. There is no gender predilection (EBM IV)^{8,112}, (EBM III).^{110,111} The atypical form of MCT occurs primarily in Siamese cats under 4 years of age. Siamese cats are also predisposed to the development of mastocytic MCT. The aetiology of feline MCT is unknown, but a genetic predisposition had been proposed in the Siamese (EBM IV).¹¹²

5.1 Clinical presentation

The typical feline cutaneous MCT is a solitary, firm, well-circumscribed, hairless, dermal nodule with superficial ulceration in 25% of lesions (Panel 6). Patients may also present with a flat, pruritic, plaque-like lesion that resembles eosinophilic granuloma, or discrete subcutaneous nodules^{8,110,113–115} (all EBM III). Intermittent pruritus, erythema and ulceration are common and Darier's sign has been reported. Approximately 20% of cats present with multiple lesions.

The head and neck are the most common sites for cutaneous MCT. Reported metastatic rates for cutaneous MCT in cats vary considerably, ranging from 0 to 22% (EBM III).^{8,110,112,113,116}

Visceral MCTs are more common in the cat than in the dog, with up to 50% of cases occurring in visceral sites (spleen, intestine). Cats are often systemically unwell for several months before diagnosis. In these patients, widespread metastasis is common. Diarrhoea is common with intestinal MCT. A cranial mediastinal form of MCT is also reported (EBM IV). Signs related to mast cell degranulation are more common in visceral or disseminated MCT^{8,110,113} (EBM III).



Panel 6. Examples of feline mastocytic MCT (A, B).

5.2 Clinical examination, biopsy and staging

The approach to feline MCT is similar to that in the dog.

Cats presenting with any of the following symptoms should be fully clinically staged, based on lymph node aspirates, abdominal ultrasound and cytology, thoracic radiographs, buffy coat smear/bone marrow aspirate if indicated (EBM IV):

- (1) Multiple nodules
- (2) Palpable abdominal abnormalities
- (3) Histologically diffuse/pleomorphic tumours
- (4) Splenic, intestinal or cranial mediastinal tumours

5.3 Prognosis

The Patnaik grading system cannot be applied to feline MCT, but histological appearance correlates with prognosis.

Mastocytic MCTs were historically subdivided into compact and diffuse forms. The mastocytic form is now divided into the well-differentiated form (formally the compact form) and the pleomorphic form (formally referred to as the diffuse form).

The well-differentiated form, which accounts for 50–90% of cases, is associated with a more benign behaviour. The pleomorphic form is histologically more anaplastic and clinically more malignant, and

carries a poorer prognosis (EBM III).^{8,110,112,114,116} Multiple cutaneous MCT carry a more guarded prognosis than solitary tumours¹¹⁰ (EBM III).

In primary splenic MCT, long-term survival (median of 12–19 months) is often achieved after splenectomy, even in the face of widespread metastasis^{8,117–119} (EBM III). Intestinal and other visceral MCT are associated with a poor prognosis^{8,110,113,119} (EBM II/III).

The value of proliferation indices has not been widely assessed in feline MCT, but high mitotic rate has been associated with aggressive behaviour^{115,120} (EBM II/III).

5.4 Treatment

5.4.1 Surgery

Fewer cats with MCT are cured by surgery than dogs, but surgery remains the best option for single, cutaneous MCTs localized in the head and/or neck¹²¹ (EBM III). It is frequently impossible to excise MCTs with wide margins, but this may be less critical for histologically well-differentiated (compact) tumours. Postsurgical recurrence rates of 0–24% are reported (EBM III)^{111,114,115}, (EBM IV).¹²² If a preoperative biopsy suggests more aggressive behaviour (pleomorphic or diffuse tumours), a wide margin of excision should be used combined with adjunctive therapy as appropriate¹¹⁵ (EBM IV). Prognostic factors such as number of lesions (multiplicity), histologic features

(pleomorphic phenotype), KIT immunoreactivity score, MI and Ki67 may help to identify potentially aggressive cases of feline cutaneous MCT¹²⁰ (EBM III).

In atypical (histiocytic) MCT, spontaneous regression may occur, but if not, marginal excision or periodical monitoring is warranted⁸ (EBM IV).

Splenectomy is indicated in splenic MCT, even in the presence of metastatic disease. Reported median survival time after splenectomy is 132 days¹²³ (EBM III).

In the intestinal form, surgery is usually not indicated as metastases which is usually widespread at presentation⁸ (EBM IV). In rare cases with an isolated lesion, enterectomy may be an option, and margins of 5–10 cm on each side are recommended⁸ (EBM IV).

5.4.2 Supportive therapy

As in dogs, the perioperative use of anti-H1 and H2 drugs may help to counteract the effects mast cell degranulation⁸ (EBM IV).

5.4.3 Radiotherapy

There are relatively few reports of radiation therapy of feline MCT, though it is a suggested treatment¹²⁴ (EBM IV). Few cats are good candidates for radiotherapy, since most cats have either multiple tumours or metastases at presentation.

In addition to external beam radiation, strontium 90 has been used in the treatment of solitary/localized lesions with local control in 98% of cases¹²⁵ (EBM III).

5.4.4 Chemotherapy

The role of chemotherapy for palliative or adjuvant treatment of feline MCT has not been clearly established. Chemotherapy is generally reserved for cats with histologically pleomorphic (diffuse), locally invasive and/or metastatic tumours. Vinblastine, chlorambucil and lomustine have been used, and one study reports an overall response rate of 50% in cats with measurable disease treated with lomustine, and a median duration of response of 168 days¹²⁶ (EBM III).

There is no proven role for corticosteroids in the treatment of feline MCT.

5.4.5 Tyrosine kinase inhibitors

Mutations in the feline *c-Kit* proto-oncogene are reported in up to 67% of MCTs (EBM III)^{127,129,130}, (EBM IV).¹²⁸ Largely, there is only anecdotal data on the use of TKIs targeting KIT in feline MCT, and the toxicity of these drugs has not been fully evaluated. However, a recent study has examined the toxicity profile of masitinib. It was given at a total dose of 50 mg per cat either daily or every other day for 4 weeks. Proteinuria was noted in (10%) cats when used daily, and neutropenia was noted in 15% of cats, along with some GI toxicity¹²⁹ (EBM II).

6 Acknowledgement

The authors would like to acknowledge the help and support of Pfizer Animal Health, the manufacturers of Toceranib.

References

1. Roudebush P, Allen TA, Dodd CE and Novotny BJ. Application of evidence-based medicine to veterinary clinical nutrition. *Journal of the American Veterinary Medical Association* 2004; **224**: 1765–1771.
2. Scott MA and Stockham SL. Basophils and mast cells. In: *Schalm's Veterinary Haematology*. 5th edn., BF Feldman, JG Zinkl and NC Jain, eds., Philadelphia, Lippincott Williams & Wilkins, 2000: 308–315.
3. Castells M. Mast cell mediators in allergic inflammation and mastocytosis. *Immunology and Allergy Clinics of North America* 2006; **26**: 465–485.
4. London CA and Seguin B. Mast cell tumours in the dog. *Veterinary Clinics of North America Small Animal Practice* 2003; **33**: 473–489.
5. McNeil EA, Prink AL and O'Brien TD. Evaluation of risk and clinical outcome of mast cell tumours in pug dogs. *Journal of Veterinary and Comparative Oncology* 2006; **4**: 2–8.
6. Mullins MN, Dernell WS, Withrow SJ, Ehrhart EJ, Thamm DH and Lana SE. Evaluation of prognostic factors associated with outcome in dogs with multiple cutaneous mast cell tumours treated with surgery with and without adjuvant treatment: 54 cases (1998–2004). *Journal of the American Veterinary Medical Association* 2006; **228**: 91–95.
7. O'Keefe DA. Canine mast cell tumours. *The Veterinary Clinics of North America. Small Animal Practice* 1990; **20**: 1105–1115.

8. Thamm DH and Vail DM. Mast cell tumours. In: *Small Animal Clinical Oncology*. 4th edn., SJ Withrow and DM Vail, eds., St. Louis, Saunders-Elsevier, 2007: 402–424.
9. Hottendorf GH and Nielsen SW. Pathologic survey of 300 extirpated canine mastocytomas. *Zentralblatt für Veterinärmedizin A* 1967; **14**: 272–281.
10. Seguin B, Leinman NF, Bregazzi VS, Ogilvie GK, Powers BE, Dernell WS, Fettman MJ and Withrow SJ. Clinical outcome of dogs with grade-II mast cell tumours treated with surgery alone: 55 cases (1996–1999). *Journal of the American Veterinary Medical Association* 2001; **218**: 1120–1123.
11. Murphy S, Sparkes AH, Blunden AS, Brearley MJ and Smith KC. Effects of stage and number of tumours on prognosis of dogs with cutaneous MCTs. *The Veterinary Record* 2006; **158**: 287–291.
12. Bostock D. The prognosis following surgical removal of mastocytomas in dogs. *The Journal of Small Animal Practice* 1973; **14**: 27–40.
13. Fox LE, Rosenthal RC, Twedt DC, Dubielzig RR, Macewen EG and Grauer GF. Plasma histamine and gastrin-concentrations in 17 dogs with mast-cell tumors. *Journal of Veterinary Internal Medicine* 1990; **4**: 242–246.
14. Howard EB, Sawa TR, Nielsen SW and Kenyon AJ. Mastocytoma and gastroduodenal ulceration. Gastric and duodenal ulcers in dogs with mastocytoma. *Pathologia Veterinaria* 1969; **6**: 146–158.
15. Baker-Gabb M, Hunt GB and France MP. Soft tissue sarcomas and mast cell tumours in dogs; clinical behaviour and response to surgery. *Australian Veterinary Journal* 2003; **81**: 732–780.
16. Withrow SJ. Cryosurgery. In: *Small Animal Clinical Oncology*. 4th edn., SJ Withrow and EG MacEwen, eds., St Louis, Saunders Co, 2007.
17. Bookbinder PF, Butt MT and Harvey HJ. Determination of the number of mast cells in lymph node, bone marrow and buffy coat cytological specimens in dogs. *Journal of the American Veterinary Medical Association* 1992; **200**: 1648–1650.
18. McManus PM. Frequency and severity of mastocytosis in dogs with and without mast cell tumours: 120 cases (1995–1997). *Journal of the American Veterinary Medical Association* 1992; **15**: 355–357.
19. Book AP, Fidel J, Wills T, Bryan J, Sellon R and Mattoon J. Correlation of ultrasound findings, liver and spleen cytology, and prognosis in the clinical staging of high metastatic risk canine mast cell tumours. *Vet Radiol Ultrasound* 2011; **52**: 548–554.
20. Finora K, Leibman NF, Fettman MJ, Powers BE, Hackett TA and Withrow SJ. Cytological comparison of fine-needle aspirates of liver and spleen of normal dogs and of dogs with cutaneous mast cell tumours and an ultrasonographically normal appearing liver and spleen. *Veterinary and Comparative Oncology* 2006; **4**: 178–183.
21. Patnaik AK, Ehler WJ and MacEwen EG. Canine cutaneous mast cell tumour: Morphologic grading and survival time in 83 dogs. *Veterinary Pathology* 1984; **21**: 469–474.
22. Welle MM, Rohrer Bley C, Howard J and Rüfenacht S. Canine mast cell tumours: a review of the pathogenesis, clinical features, pathology and treatment. *Veterinary Dermatology* 2008; **19**: 321–339.
23. Northrup NC, Harmon BG, Gieger TL, Brown CA, Carmichael KP, Garcia A, Latimer KS, Munday JS, Rakich PM, Richey LJ, Stedman NL, Cheng AL and Howerth EW. Variation among pathologists in the histologic grading of canine cutaneous mast cell tumors with uniform use of a single grading reference. *Journal of Veterinary Diagnostic Investigation* 2005; **17**: 561–564.
24. Kiupel M, Webster JD, Bailey KL, Best S, DeLay J, Detrisac CJ, Fitzgerald SD, Gamble D, Ginn PE, Goldschmidt MH, Hendrick MJ, Howerth EW, Janovitz EB, Langohr I, Lenz SD, Lipscomb TP, Miller MA, Misdorp W, Moroff S, Mullaney TP, Neyens I, O'Toole D, Ramos-Vara J, Scase TJ, Schulman FY, Sledge D, Smedley RC, Smith K, W Snyder P, Southorn E, Stedman NL, Steficek BA, Stromberg PC, Valli VE, Weisbrode SE, Yager J, Heller J and Miller R. Proposal of a 2-tier histologic grading system for canine cutaneous mast cell tumors to more accurately predict biological behaviour. *Veterinary Pathology* 2011; **48**: 147–155.
25. Dobson JM and Scase TJ. Advances in the diagnosis and management of cutaneous mast cell tumours in dogs. *The Journal of Small Animal Practice* 2007; **48**: 424–431.
26. Marconato L, Marchetti V, Francione D, Masserdotti C, Gregori M, Leotta R and Abramo F. Morphometrical approach for predicting regional lymph node micrometastatic load in canine mast cell tumours: preliminary results. *Veterinary and Comparative Oncology* 2008; **6**: 162–170.
27. Krick EL, Billings AD, Shofer FS, Watanaber S and Sorenmo KU. Cytological lymph node evaluation in dogs with mast cell tumours: association with

- grade and survival. *Veterinary and Comparative Oncology* 2009; **7**: 130–138.
28. Cahalane AK, Payne S, Barber LG, Duda LE, Henry CJ, Mauldin GE, Frimberger AE, Cotter SM and Moore AS. Prognostic factors for survival of dogs with inguinal and perineal mast cell tumours treated surgically with or without adjunctive treatment: 68 cases (1994–2002). *Journal of the American Veterinary Medical Association* 2004; **225**: 401–409.
 29. Sfiligoi G, Rassnick KM, Scarlett JM, Northrup NC and Gieger TL. Outcome of dogs with mast cell tumours in the inguinal or perineal region versus other cutaneous locations: 124 cases (1990–2001). *J Am Vet Med Assoc* 2005; **226**: 1368–1374.
 30. Iwata N, Ochiai K, Kadosawa T, Takiguchi M and Umemura T. Canine extracutaneous mast-cell tumours consisting of connective tissue mast cells. *Journal of Comparative Pathology* 2000; **123**: 306–310.
 31. Ozaki K, Yamagami T, Nomura K and Narama I. Mast cell tumours of the gastrointestinal tract in 39 dogs. *Veterinary Pathology* 2002; **39**: 557–564.
 32. Takahashi T, Kadosawa T, Nagase M, Matsunaga S, Mochizuki M, Nishimura R and Sasaki N. Visceral mast cell tumors in dogs: 10 cases (1982–1997). *Journal of The American Veterinary Medical Association* 2000; **216**: 222–226.
 33. Marconato L, Bettini G, Giacoboni C, Romanelli G, Cesari A, Zatelli A and Zini E. Clinicopathological features and outcome for dogs with mast cell tumours and bone marrow involvement. *Journal of Veterinary Internal Medicine* 2008b; **22**: 1001–1007.
 34. Zemke D, Yamini B and Yuzbasiyan-Gurkan V. Mutations in the juxtamembrane domain of KIT are associated with higher grade mast cell tumours in dogs. *Veterinary Pathology* 2002; **39**: 529–535.
 35. Webster JD, Kiupel M, Kaneene JB, Miller R and Yuzbasiyan-Gurkan V. The use of KIT and tryptase expression patterns as prognostic tools for canine cutaneous mast cell tumours. *Veterinary Pathology* 2004; **41**: 371–377.
 36. Romansik EM, Reilly CM, Kass PH, Moore PF and London CA. Mitotic index is predictive for survival for canine cutaneous mast cell tumours. *Veterinary Pathology* 2007; **44**: 335–341.
 37. Bostock DE, Crocker J, Harris K and Smith P. Nucleolar organiser regions as indicators of post-surgical prognosis in canine spontaneous mast cell tumours. *British Journal of Cancer* 1989; **59**: 915–918.
 38. Brocks BA, Neyens JJ, Teske E and Kirpensteijn J. Hypotonic water as adjuvant therapy for incompletely resected canine mast cell tumours: a randomized, double-blind, placebo-controlled study. *Veterinary Surgery* 2008; **37**: 472–478.
 39. Abadie JJ, Amardeilh MA and Delverdier ME. Immunohistochemical detection of proliferating cell nuclear antigen and Ki-67 in mast cell tumours from dogs. *Journal of the American Veterinary Medical Association* 1999; **215**: 1629–1634.
 40. Scase TJ, Edwards D, Miller J, Henley W, Smith K, Blunden A, Murphy S. Canine mast cell tumours: correlation of apoptosis and proliferation markers with prognosis. *Journal of Veterinary Internal Medicine* 2006; **20**: 151–158.
 41. McManus PM. Frequency and severity of mastocytosis in dogs with and without mast cell tumors: 120 cases (1995–97). *Journal of the American Veterinary Medical Association* 1999; **215**: 355–357.
 42. Simoes JP, Schoning P and Butine M. Prognosis of canine mast cell tumours: a comparison of three methods. *Veterinary Pathology* 1994; **31**: 637–647.
 43. Thompson JJ, Yager JA, Best SJ, Pearl DL, Coomber BL, Torres RN, Kiupel M and Foster RA. Canine subcutaneous mast cell tumors: cellular proliferation and KIT expression as prognostic indices. *Veterinary Pathology* 2011; **48**: 169–181.
 44. Govier SM. Principles of treatment for mast cell tumours. *Clinical Techniques in Small Animal Practice* 2003; **18**: 103–106.
 45. Weisse C, Shofer FS and Sorenmo K. Recurrence rates and sites for grade II canine cutaneous mast cell tumours following complete surgical excision. *Journal of the American Animal Hospital Association* 2002; **38**: 71–73.
 46. Simpson AM, Ludwig LL, Newman SJ, Bergman PJ, Hottinger HA and Patnaik AK. Evaluation of surgical margins required for complete excision of cutaneous mast cell tumours in dogs. *Journal of the American Veterinary Medical Association* 2004; **224**: 236–240.
 47. Fulcher RP, Ludwig LL, Bergman PJ, Newman SJ, Simpson AM and Patnaik AK. Evaluation of a two-centimeter lateral surgical margin for excision of grade I and grade II cutaneous mast cell tumours in dogs. *Journal of the American Veterinary Medical Association* 2006; **228**: 210–215.
 48. Schultheiss PC, Gardiner DW, Rao S, Olea-Popelka F and Tuohy JL. Association of histologic tumor characteristics and size of surgical margins with clinical outcome after surgical removal of cutaneous mast cell tumors in dogs. *Journal of the American Medical Veterinary Association* 2011; **238**: 1464–1469.

49. Murphy S, Sparkes AH, Smith KC, Blunden AS and Brearley MJ. Relationships between the histological grade of cutaneous mast cell tumours in dogs, their survival and the efficacy of surgical resection. *Veterinary Record* 2004; **154**: 743–746.
50. Stanclift RM and Gilson SD. Evaluation of neoadjuvant prednisone administration and surgical excision in treatment of cutaneous mast cell tumours in dogs. *Journal of the American Veterinary Medical Association* 2008; **232**: 53–62.
51. AlSarraf R, Mauldin GN, Patnaik AK and Meleo KA. A prospective study of radiation therapy for the treatment of grade 2 mast cell tumours in 32 dogs. *Journal of Veterinary Internal Medicine* 1996; **10**: 376–378.
52. Frimberger AE, Moore AS, LaRue SM, Gliatto JM and Bengtson AE. Radiotherapy of incompletely resected, moderately differentiated mast cell tumours in the dog: 37 cases (1989–93). *Journal of the American Animal Hospital Association* 1997; **33**: 320–324.
53. LaDue T, Price GS, Dodge R, Page RL and Thrall DE. Radiation therapy for incompletely resected canine mast cell tumours. *Veterinary Radiology and Ultrasound* 1998; **39**: 57–62.
54. Poirier VJ, Adams WM, Forrest LJ, Green EM, Dubielzig RR and Vail DM. Radiation therapy for incompletely excised grade II canine mast cell tumours. *Journal of the American Animal Hospital Association* 2006; **42**: 430–434.
55. Seguin B, McDonald DE, Kent MS, Walsh PJ and Théon AP. Tolerance of cutaneous or mucosal flaps placed into a radiation therapy field in dogs. *Veterinary Surgery* 2005; **34**: 214–222.
56. Thamm DH, Turek MM and Vail DM. Outcome and prognostic factors following adjuvant prednisone/vinblastine chemotherapy for high-risk canine mast cell tumour: 61 cases. *The Journal of Veterinary Medical Science* 2006; **68**: 581–587.
57. Hosoya K, Kisseberth WC, Alvarez FJ, Lara-Garcia A, Beamer G, Stromberg PC and Couto CG. Adjuvant CCNU (lomustine) and prednisone chemotherapy for dogs with incompletely excised grade 2 mast cell tumours. *Journal of the American Animal Hospital Association* 2009; **45**: 14–18.
58. Misdorp W. Incomplete surgery, local immunostimulation, and recurrence of some tumour types in dogs and cats. *The Veterinary Quarterly* 1987; **9**: 279–286.
59. Michels GM, Knapp DW, DeNicola DB, Glickman N and Bonney P. Prognosis following surgical excision of canine cutaneous mast cell tumours with histopathologically tumour-free versus nontumour-free margins: a retrospective study of 31 cases. *Journal of the American Animal Hospital Association* 2002; **38**: 458–466.
60. Chaffin K and Thrall DE. Results of radiation therapy in 19 dogs with cutaneous mast cell tumour and regional lymph node metastasis. *Veterinary Radiology and Ultrasound* 2002; **43**: 392–395.
61. Dobson J, Cohen S and Gould S. Treatment of canine mast cell tumours with prednisolone and radiotherapy. *Veterinary and Comparative Oncology* 2004; **2**: 132–141.
62. Davies DR, Wyatt KM, Jardine JE, Robertson ID and Irwin PJ. Vinblastine and prednisolone as adjunctive therapy for canine cutaneous mast cell tumors. *Journal of the American Animal Hospital Association* 2004; **40**: 124–130.
63. Blackwood L. Tumours of the skin and subcutaneous tissues. In: *BSAVA Manual of Canine and Feline Oncology*. Ch 12 JM Dobson and BDX Lascelles, eds., Cheltenham, BSAVA Publications, 2010: 13–158.
64. Thamm DH, Maudlin EA and Vail DM. Prednisolone and vinblastine chemotherapy for canine mast cell tumor – 41 cases (1992–97). *Journal of Veterinary Internal Medicine* 1999; **13**: 491–497.
65. Vickery KR, Wilson H, Vail DM and Thamm DH. Dose-escalating vinblastine for the treatment of canine mast cell tumour. *Veterinary and Comparative Oncology* 2008; **6**: 111–119.
66. Rassnick KM, Moore AS, Williams LE, London CA, Kintzer PP, Engler SJ and Cotter SM. Treatment of canine mast cell tumours with CCNU (lomustine). *Journal of Veterinary Internal Medicine* 1999; **13**: 601–605.
67. Cooper M, Tsai XR and Bennett P. Combination CCNU and vinblastine chemotherapy for canine mast cell tumours: 57 cases. *Veterinary and Comparative Oncology* 2009; **7**: 196–206.
68. Rassnick KM, Bailey DB, Russell DS, Flory AB, Kiselow MA, Intile JL, Malone EK, Balkman CE and Barnard SM. A phase II study to evaluate the toxicity and efficacy of alternating CCNU and high-dose vinblastine and prednisone (CVP) for treatment of dogs with high-grade, metastatic or nonresectable mast cell tumours. *Veterinary and Comparative Oncology* 2010; **8**: 138–152.
69. Camps-Palau MA, Leibman NF, Elmslie R, Lana SE, Plaza S, McKnight JA, Risbon R and Bergman PJ. Treatment of canine mast cell tumours with vinblastine, cyclophosphamide and prednisone: 35 cases (1997–2004). *Veterinary and Comparative Oncology* 2007; **5**: 156–167.

70. Taylor F, Gear R, Hoather T and Dobson J. Chlorambucil and prednisolone chemotherapy for dogs with inoperable mast cell tumours: 21 cases. *The Journal of Small Animal Practice* 2009; **50**: 284–289.
71. Rassnick KM, Al-Sarraf R, Bailey DB, Chretien JD, Phillips B and Zwhalen CH. Phase II open-label study of single-agent hydroxyurea for treatment of mast cell tumours in dogs. *Veterinary and Comparative Oncology* 2010a; **8**: 103–111.
72. McCaw DL, Milner MA, Ogilvie GK, Withrow SJ, Brewer WG, Klein MK, Bell FW and Anderson SK. Response of canine mast cell tumors to treatment with oral prednisolone. *Journal of Veterinary Internal Medicine* 1994; **8**: 406–408.
73. Skorupski KA, Hammond GM, Irish AM, Kent MS, Guerrero TA, Rodriguez CO and Griffin DW. Prospective randomized clinical trial assessing the efficacy of denamarin for prevention of CCNU-induced hepatopathy in tumor-bearing dogs. *Journal of Veterinary Internal Medicine* 2011; **25**: 838–845.
74. Letard S, Yang Y, Hanssens K, Palmerini F, Leventhal PS, Guery S, Moussy A, Kinet JP, Hermine O and Dubreuil P. Gain-of-function mutations in the extracellular domain of KIT are common in canine mast cell tumours. *Molecular Cancer Research* 2008; **6**: 1137–1145.
75. Pryer NK, Lee LB, Zadovaskaya R, Yu XM, Sukbuntherng J, Cherrington JM and London CA. Proof of target for SU11654: Inhibition of KIT phosphorylation in canine mast cell tumors. *Clinical Cancer Research*. 2003; **9**: 5729–5734.
76. Dubreuil P, Letard S, Gros L, Humbert M, Casteran N, Borge L, Hajem B, Lermet A, Sippl W, Voisset E, Arock M, Leventhal PS, Moussy A and Hermine O. Masitinib (AB1010), a potent and selective tyrosine kinase inhibitor targeting KIT. *PLOS ONE* 2009; **4**: e2758.
77. London CA, Malpas PB, Wood-Follis SL, Boucher JF, Rusk AW, Rosenberg MP, Henry CJ, Mitchener KL, Klein MK, Hintermeister JG, Bergman PJ, Couto GC, Mauldin GN and Michels GM. Multi-center, placebo-controlled, double-blind, randomized study of oral toceranib phosphate (SU11654), a receptor tyrosine kinase inhibitor, for the treatment of dogs with recurrent (either local or distant) mast cell tumour following surgical excision. *Clinical Cancer Research* 2009; **15**: 3856–3865.
78. Hahn KA, Ogilvie G, Rusk T, Devauchelle P, Leblanc A, Legendre A, Powers B, Leventhal PS, Kinet JP, Palmerini F, Dubreuil P, Moussy A and Hermine O. Masitinib is safe and effective for the treatment of canine mast cell tumors. *Journal of Veterinary Internal Medicine* 2008; **22**: 1301–1309.
79. Hahn KA, Legendre AM, Shaw NG, Phillips B, Ogilvie GK, Prescott DM, Atwater SW, Carreras JK, Lana SE, Ladue T, Rusk A, Kinet JP, Dubreuil P, Moussy A and Hermine O. Evaluation of 12- and 24-month survival rates after treatment with masitinib in dogs with nonresectable mast cell tumors. *American Journal of Veterinary Research* 2010; **71**: 1354–1361.
80. Robat C, London C, Bunting L, McCartan L, Stingle N, Selting K, Kurzman I and Vail DM. Safety evaluation of combination vinblastine and toceranib phosphate (Palladia®) in dogs: a phase I dose-finding study. *Veterinary and Comparative Oncology* 2012; **10**: 174–183.
81. Mitchell L, Thamm DH and Biller BJ. Clinical and immunomodulatory effects of toceranib combined with low-dose cyclophosphamide in dogs with cancer. *Journal Of Veterinary Internal Medicine* 2012; **26**: 355–362.
82. Carlsten KS, London CA, Haney S, Burnett R, Avery AC and Thamm DH. Multicenter prospective trial of hypofractionated radiation treatment, toceranib, and prednisone for measurable canine mast cell tumors. *Journal of Veterinary Internal Medicine* 2012; **26**: 135–141.
83. Macy DW. Canine and feline mast cell tumours: biologic behaviour, diagnosis and therapy. *Seminars in Veterinary Medicine and Surgery (small Animal)* 1986; **1**: 72–83.
84. Fan TM and de Lorimier LP. Treatment options for canine cutaneous mast cell tumours. *Veterinary Medicine* 2005; **100**: p272.
85. Rogers KS. Mast cell tumors. Dilemmas of diagnosis and treatment. *The Veterinary Clinics of North America. Small Animal Practice* 1996; **26**: 87–102.
86. Tinsley PE Jr and Taylor DO. Immunotherapy for multicentric malignant mastocytoma in a dog. *Modern Veterinary Practice Journal* 1987; **68**: 225–228.
87. Schusser EGBCG. Immunotherapy for a mast-cell neoplasm in a dog. *Wiener Tierärztliche Monatsschrift* 1990; **77**: 334–336.
88. Henry CJ, Downing S, Rosenthal RC, Klein MK, Meleo K, Villamil JA, Fineman LS, McCaw DL, Higginbotham ML and McMichael J. Evaluation of a novel immunomodulator composed of human chorionic gonadotropin and bacillus Calmette-Guerin for treatment of canine mast cell tumours in clinically affected dogs. *American Journal of Veterinary Research* 2007; **68**: 1246–1251.

89. Grier RL and Di Guardo G. Deionised water and mast cell tumours. *The Journal of Small Animal Practice* 2000; **41**: 368–371.
90. Grier RL, DiGuardo G, Myers R and Merkley DF. Mast cell tumour destruction in dogs by hypotonic solution. *The Journal of Small Animal Practice* 1995; **36**: 385–388.
91. Gieger T, Northrup N and Wall M. Clinical management of mast cell tumours in dogs. *Compendium on Continuing Education for the Practicing Veterinarian* 2005; **27**: 56–68.
92. Jaffe MH, Hosgood G, Kerwin SC, Hedlund CS and Taylor HW. Deionised water as an adjunct to surgery for the treatment of canine cutaneous mast cell tumours. *The Journal of Small Animal Practice* 2000; **41**: 7–11.
93. Neyens IJ, Kirpensteijn J, Grinwis GC and Teske E. Pilot study of intraregional deionised water adjunct therapy for mast cell tumours in dogs. *The Veterinary Record* 2004; **154**: 90–91.
94. Legorreta RA, Denman DL, Kelley MC and Lewis GC Jr. Use of hyperthermia and radiotherapy in treatment of a large mast cell sarcoma in a dog. *J Am Vet Med Assoc* 1988; **193**: 1545–1548.
95. Thrall DE and Dewhirst MW. Use of radiation and/or hyperthermia for treatment of mast cell tumours and lymphosarcoma in dogs. *The Veterinary Clinics of North America. Small Animal Practice* 1985; **15**: 835–843.
96. Dougherty TJ, Thoma RE, Boyle DG and Weishaupt KR. Interstitial photoradiation therapy for primary solid tumours in pet cats and dogs. *Cancer Research* 1981; **41**: 401–404.
97. Cheli R, Addis F, Mortellaro CM, Fonda D, Andreoni A and Cubeddu R. Hematoporphyrin derivative photochemotherapy of spontaneous animal tumours: clinical results with optimized drug dose. *Cancer Letters* 1984; **23**: 61–66.
98. Thoma RE. Photodynamic therapy. In: *Clinical veterinary oncology*. SJ Withrow and EG MacEwen Eds., Philadelphia, JB Lippincott Co, 1989: 124–127.
99. Roberts WG, Klein MK, Loomis M, Weldy S and Berns MW. Photodynamic therapy of spontaneous cancers in felines, canines, and snakes with chloro-aluminum sulfonated phthalocyanine. *Journal of the National Cancer Institute* 1991; **83**: 18–23.
100. Frimberger AE, Moore AS, Cincotta L, Cotter SM and Foley JW. Photodynamic therapy of naturally occurring tumours in animals using a novel benzophenothiazine photosensitizer. *Clinical Cancer Research* 1998; **4**: 2207–2218.
101. Lucroy MD, Edwards BF and Madewell BR. Veterinary photodynamic therapy. *Journal of the American Veterinary Medical Association* 2000; **216**: 1745–1751.
102. Tanabe S, Yamaguchi M, Iijima M, Nakajima S, Sakata I, Miyaki S, Takemura T, Furuoka H, Kobayashi Y, Matsui T, Uzuka Y and Sarashina T. Fluorescence detection of a new photosensitizer, PAD-S31, in tumour tissues and its use as a photodynamic treatment for skin tumours in dogs and a cat: a preliminary report. *The Veterinary Journal* 2004; **167**: 286–293.
103. Krahwinkel DJ Jr. Cryosurgical treatment of skin diseases. *The Veterinary Clinics of North America. Small Animal Practice* 1980; **10**: 787–801.
104. Roberts SM, Severin GA and Lavach JD. Prevalence and treatment of palpebral neoplasms in the dog: 200 cases (1975–1983). *Journal of the American Veterinary Medical Association* 1986; **189**: 1355–1359.
105. Tozon N, Sersa G and Cemazar M. Electrochemotherapy: potentiation of local antitumour effectiveness of cisplatin in dogs and cats. *Anticancer Research* 2001; **21**: 2483–2488.
106. Spugnini EP, Vincenzi B, Citro G, Dotsinsky I, Mudrov T and Baldi A. Evaluation of Cisplatin as an electrochemotherapy agent for the treatment of incompletely excised mast cell tumors in dogs. *Journal of Veterinary Internal Medicine* 2011; **25**: 407–411.
107. Kodre V, Cemazar M, Pecar J, Sersa G, Cor A and Tozon N. Electrochemotherapy compared to surgery for treatment of canine mast cell tumours. *In Vivo* 2009; **23**: 55–62.
108. Spugnini EP, Vincenzi B, Baldi F, Citro G and Baldi A. Adjuvant electrochemotherapy for the treatment of incompletely resected canine mast cell tumours. *Anticancer Research* 2006; **26**: 4585–4589.
109. Rogers KS. Common questions about diagnosis and treating canine mast cell tumours. *Veterinary Medicine* 1993; **88**: 246–250.
110. Litster AL and Sorenmo KU. Characterisation of the signalment, clinical and survival characteristics of 41 cats with mast cell neoplasia. *Journal of Feline Medicine and Surgery* 2006; **8**: 177–183.
111. Wilcock BP, Yager JA and Zink MC. The morphology and behaviour of feline cutaneous mastocytomas. *Veterinary Pathology* 1986; **23**: 320–324.
112. Chastain CB, Turk MAM and O'Brien D. Benign cutaneous mastocytomas in two litters of Siamese

- kittens. *Journal of the American Veterinary Medical Association* 1988; **193**: 959–960.
113. Antognoni MT, Spaterna A, Lepri E, Fruganti A and Laus F. Characteristic clinical, haematological, and histopathological findings in feline mastocytoma. *Veterinary Research Communications* 2003; **27**(Suppl. 1): 727–730.
 114. Buerger RG and Scott DW. Cutaneous mast cell neoplasia in cats: 14 cases (1975–1985). *Journal of the American Veterinary Medical Association* 1987; **190**: 1440–1444.
 115. Johnson TO, Schulman FY, Lipscomb TP and Yantis LD. Histopathology and biologic behavior of pleomorphic cutaneous mast cell tumours in fifteen cats. *Veterinary Pathology* 2002; **39**: 452–457.
 116. Molander-McCrary H, Henry CJ, Potter K, Tyler JW and Buss MS. Cutaneous mast cell tumours in cats: 32 cases (1991–1994). *Journal of the American Animal Hospital Association* 1998; **34**: 281–284.
 117. Guerre R, Milet P and Groulade P. Systemic mastocytosis in cat: remission after splenectomy. *JSAF* 1979; **20**: 769–722.
 118. Liska WD, MacEwen EG, Zaki FA and Garvey M. Feline systemic mastocytosis: a review and results of splenectomy in seven cases. *JAAHA* 1979; **15**: 589–597.
 119. Feinmehl R, Matus R, Mauldin GN and Patnaik AK. Splenic mast cell tumours in 43 cats (1975–1992). *Proceedings Annual Conference of the Veterinary Cancer Society* 1992; **12**: 50.
 120. Sabattini S and Bettini G. Prognostic value of histologic and immunohistochemical features in feline cutaneous mast cell tumours. *Veterinary Pathology* 2010; **47**: 643–653.
 121. Montgomery KW, van der Woerd A, Aquino SM, Sapienza JS and Ledbetter EC. Periocular cutaneous mast cell tumors in cats: evaluation of surgical excision (33 cases). *Veterinary Ophthalmology* 2010; **13**: 26–30.
 122. Buss MS, Mollander H, Potter K, Henry CJ and Tyler JW. Predicting survival and prognosis in cats with cutaneous mastocytomas of varying histological grade. *Proceedings Annual Conference VCS* 1996; **16**: 56–57.
 123. Gordon SSN, McClaran JK, Bergman PJ and Liu SM. Outcome following splenectomy in cats. *Journal of Feline Medicine and Surgery* 2010; **12**: 256–261.
 124. Ogilvie GK and Moore AS. Radiation therapy – properties, uses and patient management. In: *Feline Oncology*. 1st edn., GK Ogilvie and AS Moore, eds., Trenton NJ, Veterinary Learning Systems, 1990: 77–84.
 125. Turrel JM, Farely J, Page RL and McEntee MC. Evaluation of strontium 90 irradiation in treatment of cutaneous mast cell tumors in cats. *Journal of the American Veterinary Medical Association* 2006; **228**: 898–901.
 126. Rassnick KM, Williams LE, Kristal O, Al-Sarraf R, Baez JL, Zwahlen CH and Dank G. Lomustine for treatment of mast cell tumours with in cat: 38 cases (1999–2005). *Journal of the American Veterinary Medical Association* 2008; **232**: 1200–1205.
 127. Dank G, Chien MB and London CA. Activating mutations in the catalytic or juxtamembrane domain of c-kit in splenic mast cell tumours of cats. *American Journal of Veterinary Research* 2002; **63**: 1129–1133.
 128. Isotani M, Tamura K, Yagihara H, Hikosaka M, Ono K, Washizu T and Bonkobara M. Identification of a c-kit exon 8 internal tandem duplication in a feline mast cell tumour case and its favorable response to the tyrosine kinase inhibitor imatinib mesylate. *Veterinary Immunology and Immunopathology* 2006; **114**: 168–172.
 129. Isotani M, Yamada O, Lachowicz JL, Tamura K, Yagihara H, Fujino Y, Ono K, Washizu T and Bonkobara M. Mutations in the fifth immunoglobulin-like domain of kit are common and potentially sensitive to imatinib mesylate in feline mast cell tumours. *British Journal of Haematology* 2010; **148**: 144–153.
 130. Daly M, Sheppard S, Cohen N, Nabity M, Moussy A, Hermine O and Wilson H. Safety of masitinib mesylate in healthy cats. *Journal of Veterinary Internal Medicine* 2011; **25**: 297–302.