

Received: 2017.01.04
Accepted: 2017.02.02
Published: 2017.04.02

Gall Bladder Agenesis: A Rare Embryonic Cause of Recurrent Biliary Colic

Authors' Contribution:
Study Design A
Data Collection B
Statistical Analysis C
Data Interpretation D
Manuscript Preparation E
Literature Search F
Funds Collection G

AEF 1,2 **Aarthi Rajkumar**
BDF 1 **Albina Piya**

1 Department of Internal Medicine, Canton Medical Education Foundation, Canton, OH, U.S.A.
2 Department of Internal Medicine, Northeast Ohio Medical University (NEOMED), Rootstown, OH, U.S.A.

Corresponding Author: Aarthi Rajkumar, e-mail: aarthirajkumar96@gamil.com, aarthi.rajkumar@aultman.com
Conflict of interest: None declared

Patient: Female, 24
Final Diagnosis: Gallbladder agenesis
Symptoms: —
Medication: —
Clinical Procedure: —
Specialty: Gastroenterology and Hepatology

Objective: Rare disease





Background: Gallbladder agenesis (GA) is an extremely rare anatomic anomaly with a reported incidence of less than 0.5%. It is usually asymptomatic, but can present with features of biliary colic and cholecystitis. We present here a case of GA in a patient with recurrent biliary colic.

Case Report: A 24-year-old African American woman presented with recurrent episodes of right upper-quadrant abdominal pain. During her first episode, she was found to have elevated transaminases and clinical features of cholecystitis, but ultrasound did not visualize a gallbladder and she was discharged with a diagnosis of biliary colic. She returned within a week with worsening liver enzymes, severe pain, and vomiting. A hepatobiliary iminodiacetic acid (HIDA) scan was done, which again did not show the gall bladder. On clinical suspicion of acute cholecystitis, she underwent laparoscopic surgery. Intraoperatively, the gall bladder fossa was empty and a diagnosis of gall bladder agenesis was made. She presented a third time with similar complaints and magnetic resonance cholangiopancreatography (MRCP) was done, which showed normal biliary tract anatomy and absent gall bladder. A diagnosis of sphincter of Oddi dysfunction was made and she was discharged on antispasmodics.

Conclusions: Diagnosing GA is challenging. The rarity of this entity combined with classic clinical features of cholecystitis and non-visualization of the gall bladder on routine investigation prompts unnecessary surgical intervention. Awareness of this condition, along with use of better imaging modalities like preoperative MRCP, can aide physicians to appropriately manage this uncommon clinical condition.

MeSH Keywords: Colic • Congenital Abnormalities • Gallbladder Diseases • Sphincter of Oddi Dysfunction

Full-text PDF: <http://www.amjcaserep.com/abstract/index/idArt/903176>

 1667   4  17



Background

Gall bladder agenesis (GA) or congenital absence of gall bladder (CAGB) is a rare embryonic anomaly with a reported incidence of less than 1 in 6000 live births [1]. Most cases remain asymptomatic and are discovered at autopsy; however, approximately 50% of these present with biliary colic mimicking a clinical picture of acute cholecystitis or choledocholithiasis [2,3]. Standard imaging modalities like ultrasound and nuclear studies cannot accurately diagnose this condition [4,5]; hence, patients are subjected to unnecessary surgical interventions [6]. With advances in imaging technology, a preoperative diagnosis of GA can be made when the gall bladder is not visualized by standard diagnostic tests, avoiding the need for surgery [7]. Although there are no defined guidelines on diagnosis and management of this rare entity, some authors recommend a dedicated imaging of the biliary tree using MRCP or endoscopic ultrasound when there is a diagnostic uncertainty with gall bladder non-visualization [8,9]. We present here a challenging case of a young patient with recurrent biliary colic who underwent laparoscopic surgery for her symptoms and was eventually diagnosed with gall bladder agenesis and sphincter of Oddi dysfunction.

Case Report

A healthy 24-year-old African American woman presented with repeated episodes of right upper-quadrant abdominal pain associated with nausea. In the first hospital visit, she was anicteric on exam but had a positive Murphy's sign. Liver enzymes were deranged with an alkaline phosphatase of 177 u/L, aspartate aminotransferase (AST) of 159 u/L, alanine aminotransferase (ALT) of 131u/L, and normal bilirubin. Abdominal ultrasound was done, but the gall bladder could not be visualized, and it was thought to be either contracted or filled with stones (Figure 1). She was diagnosed with a biliary colic and managed conservatively. An elective cholecystectomy was planned to occur 6 weeks later. She returned within 1 week with progressive abdominal pain and vomiting. This time her clinical exam results were unchanged from the prior visit; however, her white blood cell count was elevated at 14 000 cells/mm³, AST had increased to 280 u/L, ALT was 171 u/L, alkaline phosphatase was 250 u/L, and gamma glutamyl transferase was 314 u/L. She underwent a hepatobiliary iminodiacetic acid (HIDA) scan, which again did not reveal the gall bladder, despite morphine augmentation (Figure 2). The differential diagnosis at this time was acute cholecystitis with obstructed cystic duct, chronically fibrosed gall bladder, or gall bladder agenesis. She was admitted to the hospital for management of her intractable nausea and vomiting, with a clinical diagnosis of suspected acute cholecystitis. Despite adequate analgesics and antibiotics, her clinical and laboratory

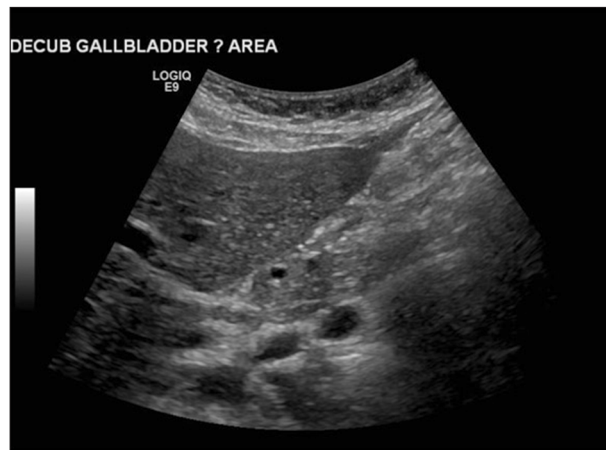

Figure 1. Ultrasound of abdomen with non-visualized gall bladder.

parameters did not improve and she was taken to the operating room for a laparoscopic cholecystectomy. Intraoperatively, the gall bladder fossa was empty (Figure 3) and the surgeons were unable to locate any ectopic gall bladder tissue; therefore, a diagnosis of agenesis of gallbladder was made. The patient was discharged home after an uneventful post-operative stay. She came back within 1 month with similar abdominal pain and elevated liver enzymes. At this time, gastroenterology was consulted and a magnetic resonance cholangiopancreatography (MRCP) was done with a plan for endoscopic retrograde cholangiopancreatography (ERCP) if any abnormality was noted. There was no stone and no evidence of stricture or other biliary pathology, and the gall bladder was again absent (Figure 4). The pain was attributed to a possible sphincter of Oddi dysfunction and she was provided reassurance and discharged on opiates and antispasmodics. The patient continued to have more episodes of right upper-quadrant abdominal pain; however, she responded well to pain control and antispasmodics. Although ERCP and sphincterotomy were considered as therapeutic alternatives, they were deferred as she responded well to medical treatment.

Discussion

Gall bladder agenesis is an extremely rare anatomic anomaly. It was first reported in the early 18th century by Lemery and since then there have been sporadic reports of this condition in the medical literature [1,10]. The incidence in the general population is reported to be around 13–65/10 000, while many more have been discovered on autopsies. GA results from failure of development of the caudal part of the hepatic diverticulum during embryogenesis. Many cases are asymptomatic, but symptoms occur in about 50% of patients. GA can also be associated with other congenital anomalies, like cardiac septal defects, duodenal atresia, imperforate anus, pancreatic

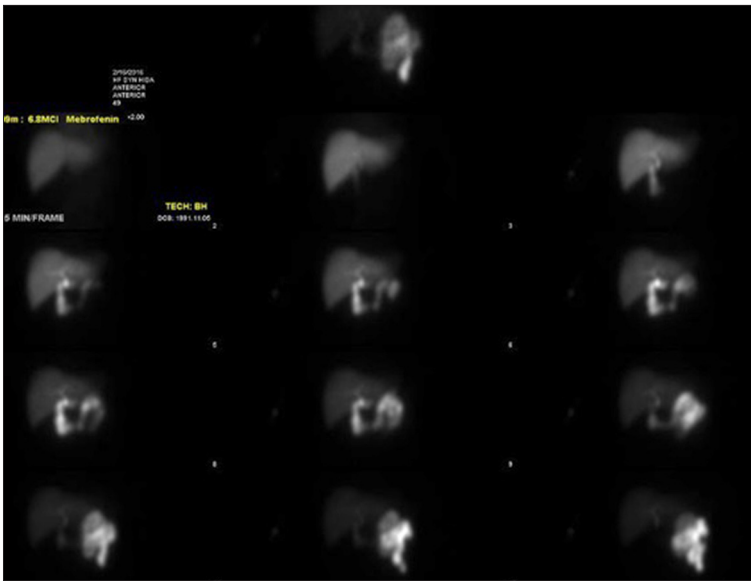


Figure 2. Hepatobiliary iminodiacetic acid (HIDA) scan showing absence of uptake by the gall bladder.

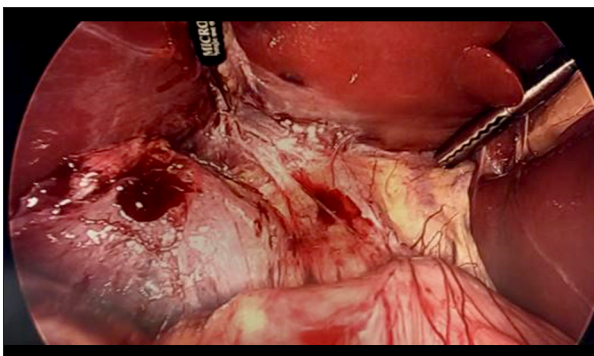


Figure 3. Intraoperative image shows an empty gall bladder fossa.

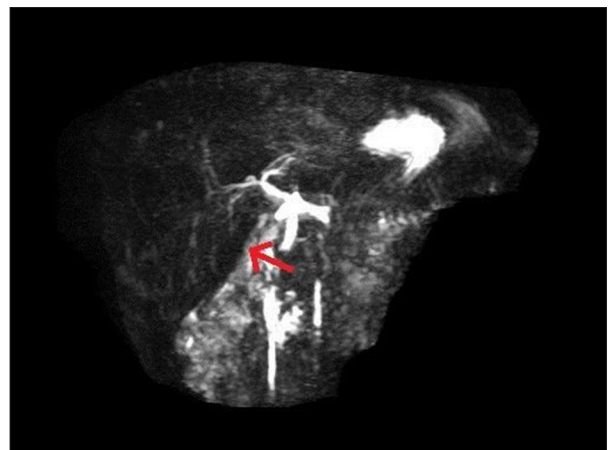


Figure 4. Coronal MIP (maximum intensity projection) reformat of the hepatobiliary tree on MRCP showing absence of gall bladder (red arrow).

divisum, and renal agenesis [11]. The first comprehensive review of the condition was published in 1988 by Bennion et al, who categorized GA into 3 types depending on clinical presentation: a) those with multiple fetal anomalies, b) asymptomatic patients, and c) symptomatic patients [1]. A more recent review of a larger series of cases simplifies Bennion's classification into just type 1 (symptomatic) and type 2 (asymptomatic). Type 1 is further subdivided into 1a, which includes GA associated with lethal congenital malformations like imperforate anus, duodenal atresia, biliary atresia, and septal defects, and 1b, which are those with other associated abnormalities like intestinal malrotation, choledochal cyst, and choledochectasia, and patients presenting with symptoms of biliary colic [12]. In this same series, type 1b accounted for 94% of patients with GA and most of them had biliary colic. Alzahrani et al. reported a rare case of GA associated with situs inversus totalis and choledocholithiasis, and described in detail the mechanism of pain in patients with symptomatic GA [13]. In symptomatic patients, the most common clinical presentation is right upper-quadrant pain mimicking biliary

colic. The cause of biliary colic in patients with an absent gall bladder is attributed to sphincter of Oddi dysfunction and biliary dyskinesia, which in turn promotes biliary stasis, infection, and choledocholithiasis [12–14].

As biliary colic and elevated liver enzymes are the predominant presenting symptoms, most cases of GA are misdiagnosed as cholecystitis or choledocholithiasis [15]. Ultrasound is the standard diagnostic test for patients with biliary colic, and if the gall bladder cannot be visualized, the classic WES triad (wall, echo, shadow) helps to differentiate a gallbladder filled with stones from a contracted one that is difficult to visualize [4], although there are times when ultrasound alone is insufficient to diagnose gall stone disease and radionuclide imaging studies such as HIDA can be used in these circumstances. Non-visualization of the gallbladder on HIDA scan is

considered a typical finding of acute cholecystitis; it can occur in other conditions like chronic cholecystitis, cystic duct obstruction by tumor, prolonged fasting, pancreatitis, alcoholism, parenteral hyperalimentation, and gall bladder agenesis [5]. In many clinical situations, the classic features of cholecystitis and non-visualization of the gall bladder on routine investigation prompt unnecessary surgical intervention [6,8,15,16]. If GA is discovered intraoperatively, then a search for ectopic sites of gall bladder tissue is recommended. Often, laparoscopic surgery is converted to an explorative laparotomy in a futile search for the gallbladder, increasing the risk of iatrogenic damage to hepatobiliary structures during surgical dissection and increasing the risk of mortality and morbidity [10,11]. Some authors recommend intraoperative cholangiography to better identify the biliary anatomy, while others suggest a conservative approach and opt for post-operative imaging using ultrasound or MRCP [16].

With the advent of sophisticated imaging techniques, preoperative diagnosis of GA is possible [7,8]. Malde recommends noninvasive modalities like MRCP or computerized tomographic scan before considering ERCP or endoscopic ultrasound if the gall bladder is not visualized in a patient presenting with biliary symptoms. He even suggests repeating the imaging studies after resolution of the acute phase if there is initial diagnostic uncertainty [8]. A paper published by Bani-Hani suggests that there may also be a role for abdominal computerized tomography scanning in patients with equivocal or non-diagnostic ultrasound results [15]. In our patient, diagnosis and management were challenging. Clinical and laboratory features favored acute cholecystitis and although ultrasound and HIDA scan were inconclusive, the patient was subjected to surgery based on clinical features. Had MRCP been considered on the second admission, the diagnosis of GA could have been made preoperatively and an unnecessary surgical procedure could have been avoided.

There are no specific guidelines for treating GA. Most patients continue to experience biliary colic type of pain pre- and post-operatively. The cause of pain in patients with GA is akin to post-cholecystectomy syndrome pain that occurs due to dilatation of the common bile duct in an attempt to store bile,

resulting in increased pressure in the sphincter of Oddi [1,12,14]. It is postulated that the hepatic duct takes on the role of bile storage in the absence of the anatomical gall bladder and this predisposes to cholestasis, infection, and cholelithiasis [15,16]. In most cases, conservative management with analgesics and smooth muscle relaxants usually relieves the pain [2,16]. In some instances, there is spontaneous resolution of pain after surgery, probably due to lysis of periportal and right hypochondrial adhesions [1,14,15]. Some authors believe that patients with GA are prone to biliary calculi and recurrent colicky pain due to the increased biliary stasis and common bile duct dilatation, and that these patients with choledocholithiasis in the setting of GA should be considered for ERCP and stone extraction [14]. If patients with GA continue to experience biliary colic, further testing with CT scan, biliary manometry, upper-gastrointestinal endoscopy, and ERCP with or without sphincterotomy can be attempted [15]. A more recent study suggests functional abdominal pain syndrome related to visceral hypersensitivity as a cause of unexplained biliary colic, and a combination of antispasmodics like hyoscyamine and a low-dose antidepressant such as amitriptyline is recommended [17]. The patient presented here continued to have colicky biliary-type pain after surgery. Sphincter dyskinesia was the primary consideration and ERCP/sphincterotomy was also contemplated; however, she responded well to conservative treatment, sparing the need for more invasive procedures.

Conclusions

Biliary colic is a common presenting complaint for which patients are admitted to the hospital. A heightened awareness of delayed presentation of congenital anomalies, along with use of better imaging modalities like MRCP, can help physicians to appropriately diagnose this uncommon clinical condition. Functional causes of unrelenting pain should also be considered and a trial of medical management is appropriate in such situations prior to surgical intervention.

Conflict of interest

The authors declare no conflict of interest.

References:

1. Bennion RS, Thompson JE, Tompkins RK: Agenesis of gallbladder without extrahepatic biliary atresia. *Arch Surg*, 1988; 123: 1257–60
2. Kasi PM, Ramirez R, Rogal SS et al: Gallbladder agenesis. *Case Rep Gastroenterol*, 2011; 5: 654–62
3. Kabiri H, Domingo OH, Tzarnas CD: Agenesis of the gallbladder. *Curr Surg*, 2006; 63: 104–6
4. MacDonald FR, Cooperberg PL, Cohen MM: The WES triad: A specific sonographic sign of gallstones in the contracted gallbladder. *Gastrointest Radiol*, 1981; 6: 39–41
5. Dickinson CZ, Powers TA, Sandler MP, Partain CL: Congenital absence of the gall bladder: Another cause of false positive hepatobiliary image. *J Nucl Med*, 1984; 25: 70–72
6. Owen RP, Botros M, Uzair S: Two cases of gallbladder agenesis diagnosed at planned cholecystectomy – lessons learned. *The Internet Journal of Surgery* 2011; 26(1)
7. Fiaschetti V, Calabrese G, Viarani S et al: Gallbladder agenesis and cystic duct absence in an adult patient diagnosed by magnetic resonance cholangiography: Report of a case and review of the literature. *Case Rep Med*, 2009; 2009: 674768

8. Malde S: Gallbladder agenesis diagnosed intra-operatively: A case report. *J Med Case Reports*, 2010; 4: 285–90
9. Balakrishnan S, Singhal T, Grandy-Smith S, El-Hasani S: Agenesis of the gallbladder: Lessons to learn. *JSLS*, 2006; 10: 517–19
10. Velimezis G, Perrakis E, Perrakis A: Agenesis of the gallbladder: What to do in such a rare case? Presentation of a case and review of the literature. *The Internet Journal of Surgery* 2010; 26(2)
11. Stephenson JA, Norwood M, Al-Leswas D, et al. Hepatic haemangioma masquerading as the gallbladder in a case of gallbladder agenesis: A case report and literature review. *HPB Surg* 2010; 2010. pii: 971609
12. Tang L-M, Wang X-F, Ren P-T et al: The diagnosis of gallbladder agenesis: Two cases report. *Int J Clin Exp Med*, 2015; 8: 3010–16
13. Alzahrani HA, Yamani NM: Gallbladder agenesis with a primary choledochal stone in a patient with situs inversus totalis. *Am J Case Rep*, 2014; 15: 185–88
14. Pierro A, Martucci M, Maselli G, Farchione A: Agenesis of the gallbladder with the presence of a small dysmorphic cyst: Role of magnetic resonance cholangiopancreatography. *J Clin Imaging Sci*, 2012; 2: 17
15. Bani-Hani KE: Agenesis of the gallbladder: Difficulties in management. *J Gastroenterol Hepatol*, 2005; 20: 671–75
16. Scobie JL, Bramhall SR: Congenital agenesis of the gallbladder: A UK case report. *Oxf Med Case Reports*, 2016; 8: 176–78
17. Wilcox CM: Sphincter of Oddi dysfunction Type III: New studies suggest new approaches are needed. *World J Gastroenterol*, 2015; 21: 5755–61