



## Case Report

# Sternalis muscle: importance of its awareness in chest imaging and clinical significance

Published online June 10th, 2011 © <http://www.ijav.org>

Grace PINHAL-ENFIELD

Paolo VARRICCHIO

David O. DeFOUW

Nagaswami S. VASAN ✦

University of Medicine and Dentistry of New Jersey, New Jersey Medical School,  
Department of Cell Biology and Molecular Medicine, Newark, New Jersey, USA.



✦ Dr. Nagaswami S. Vasani  
University of Medicine and Dentistry of New Jersey  
New Jersey Medical School  
Department of Cell Biology and Molecular Medicine  
185 South Orange Avenue  
Medical Science Building 6671  
Newark, New Jersey 07103, USA.  
☎ +1 973 972-5243  
✉ [vasanns@umdnj.edu](mailto:vasanns@umdnj.edu)

Received October 11th, 2010; accepted January 29th, 2011

## ABSTRACT

The sternalis is an uncommon, variant muscle of the anterior thoracic wall that is estimated to be present in 8% of the human population. Students in a medical gross anatomy course were fortunate to discover a right, unilateral sternalis muscle during dissection of a female cadaver. Despite its rarity, radiologists must be aware of the possibility of encountering the sternalis during thoracic imaging (CT scans, mammography, MRI) because of the risk for its misdiagnosis as a tumor. Further, risk for surgical complications such as damage to this muscle during breast surgery must be considered. Thus, although it may be difficult to perform a proper anatomic analysis of the infrequently observed sternalis muscle, it is important that students and clinicians be aware of its existence because of its potentially significant impact on clinical diagnosis and patient management. © IJAV. 2011; 4: 106–108.

**Key words** [muscle] [sternalis] [pectoral] [intercostal] [mammography]

## Introduction

The sternalis is a rarely encountered subcutaneous muscle band in the anterior thoracic wall. Although it has been observed often in varying forms, the sternalis typically lies parallel to the sternum over the medial border of the pectoralis major as it extends from the upper sternum to the costal region [1]. It is present in 8% of the population, with variable frequencies among different ethnic groups (ranging from 2% in European Caucasians to 11% in Asians) and increased association with other variations (high occurrence in anencephalic fetuses) [1–3]. Possible functions for the sternalis include proprioception and respiration [1,4,5]. Based on supply by the pectoral and/or intercostal nerves, it has been proposed that the sternalis is part of the pectoral and/or abdominal muscle groups, respectively [6].

Although a rare variant, the advent of diagnostic imaging requires awareness of the sternalis by clinicians (especially radiologists) because of its potential misdiagnosis as a tumor or complication during surgery [1,2].

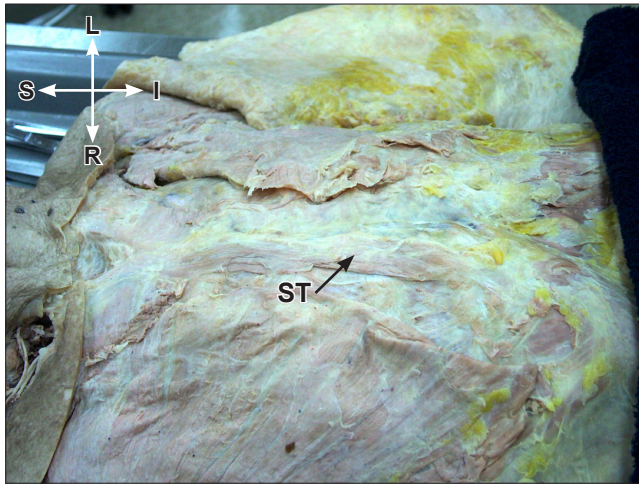
## Case Report

A unilateral sternalis muscle was exposed while reflecting the skin and superficial fascia of the right pectoral region during routine cadaveric dissection in an anatomy course for medical students at the New Jersey Medical School (Newark,

NJ). The individual was a 76-year-old Caucasian female who had died of cardiac arrhythmia. The sternalis appeared as a ribbon-like strap and measured 15 cm in length with an average width of 2.5 cm. It was oriented on the anterior thoracic wall along the right margin of the sternum and medial to the sternocostal head of the right pectoralis major muscle (Figures 1, 2). The sternalis was attached superiorly by an aponeurotic sheet to the right side of the manubrium sterni at the level of the first right costal cartilage. The inferior tendinous attachment was located on the medial end of the sixth right costal cartilage and partially extended onto the right rectus abdominis muscle. The 3rd–5th intercostal nerves entered the muscle from its deep aspect (feature not photographed). The ipsilateral pectoralis major did not display morphological variation.

## Discussion

The sternalis is a rare muscle of the anterior thoracic wall and has been defined in the anatomic literature (since 1604) by different synonyms, including episternalis, presternalis, parasternalis, anomalous sterni, sternalis brutorum, rectus sternalis, rectus sterni, superficial rectus sterni, rectus thoracic and rectus thoracis superficialis [1,2]. Although many variations of the sternalis have been observed, it typically appears as a unilateral or bilateral flat muscle whose thickness ranges from a narrow ribbon to a broad



**Figure 1.** Figure shows the actual cadaver specimen with right sternalis muscle. (*ST: sternalis muscle*)

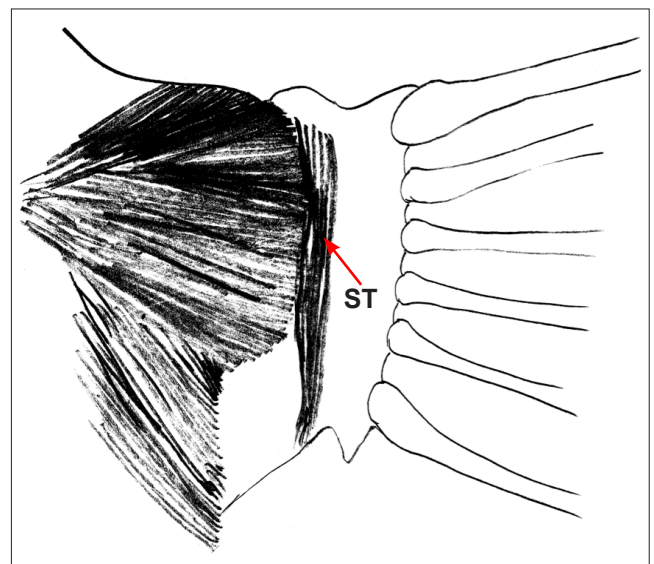
strap, occasionally with tendinous insertions [1,2,6]. The length of the longitudinally-oriented sternalis varies with attachments superiorly in the infraclavicular region (e.g., pectoral fascia, sternal head of the sternocleidomastoid, manubrium, or costal cartilages) and inferiorly on the chest wall (e.g., lower costal cartilages, sheath of the rectus abdominis, or aponeurosis of the external oblique) [1,7,8]. The subcutaneous sternalis runs about 2.5 cm parallel or oblique to the lateral border of the sternum and is superficial and medial to the pectoralis major [2,7,9]. Although the medial border of the pectoralis major may be partly covered by the sternalis and may be smaller in the presence of the sternalis, there are no functional deficits of the pectoralis major associated with its presence [2].

Case reports have indicated a variable nerve supply to the sternalis. It may be innervated by the pectoral nerves (55%), intercostal nerves (43%), or both (2%) [4,6,9,10]. The sternalis has been grouped with the pectoral muscle group (pectoralis major) and with the abdominal muscle group (rectus abdominis and external oblique) because of common innervations. Supply by more than one nerve may result from fusion of separate muscle bellies into a single sternalis muscle [8]. The sternalis is primarily supplied by internal thoracic artery (via anterior) intercostal arteries and sometimes by the thoracoacromial artery [2].

Suggestions about the functional significance of the sternalis include elevation of the lower chest region during inspiration (based on attachment sites) and proprioception for movements of the thoracic wall [1,4,5]. Although controversial, it has been theorized that the sternalis is a vestigial remnant of evolutionary development. It has been compared to the superficial, subcutaneous panniculus carnosus muscle, which hampers bird perching on the backs of grazing animals and transforms echidna's body shape to present spines to predators [7 and references there in]. The panniculus carnosus is composed of a superficial layer

from which the platysma originates and a deep layer with insertions into the sternocleidomastoid and external oblique aponeurosis. Thus, the sternalis may represent a typically missing, intermediately-located remnant of the link between components of the deep panniculus carnosus [7]. Origins of the sternalis, along with the pectoralis and abdominal muscles, from the thoracoabdominal abaxial precursors of the ventrolateral edge during embryonic development and innervation by pectoral nerves and/or intercostal nerves further support belief that the sternalis is a variant of or an extension of the pectoralis major and/or abdominal muscles (rectus abdominis or external oblique) [7,8,10].

Although the presence of the sternalis is typically without consequence, awareness of its potential existence by clinicians is important because of its topographical variations and its potential negative impact on diagnosis and surgery in the chest wall region [2]. For example, the presence of the sternalis has been coupled with variations in the pectoralis major, adrenal gland, and skull (e.g., high frequency in anencephalic fetuses) [2,7]. Further, it has been discovered during surgery for mastectomy or breast reconstruction or as an irregular medial density mimicking a malignant lesion on mammography or CT. In the latter case, unnecessary intrusive testing such as biopsy would often be required [2,9]. Hence, the presence of a sternalis muscle and its variable presentations may require adaptations and adjustments during radiation therapy for breast cancer or during surgery. Although a reliable method for detecting the sternalis has not been established, fixing the elbow in a flexed position and moving the arm in a horizontal direction toward the opposite anterior superior iliac spine tenses the muscle to expedite its detection [2].



**Figure 2.** Schematic illustration of the cadaveric specimen shown in Figure 1. (*ST: sternalis muscle*)

Although the sternalis is a rare anatomic variant with typically no negative associations, it may be encountered several times throughout the course of a clinician's career and thus create potentially significant implications for diagnosis and surgery in the chest region. Unfortunately, a general lack of awareness about the sternalis exists among

many healthcare providers, including surgeons, radiologists, and medical students [2]. Therefore, anatomic studies through dissections, illustrations, photographs, diagnostic images, and detailed descriptions are warranted to increase awareness of the sternalis muscle and its variations among clinicians (especially radiologists and surgeons) [1,2].

## References

- [1] Zaher WA, Darwish HH, Abdalla AME, Vohra MS, Khan MM. Sternalis: a clinically important variation. *Pak J Med Sci.* 2008; 25: 325–328.
- [2] Schulman MR, Chun JK. The conjoined sternalis-pectoralis muscle flap in immediate tissue expander reconstruction after mastectomy. *Ann Plast Surg.* 2005; 55: 672–675.
- [3] Shepherd F. On the musculus sternalis occurring in anencephalous monsters. *Transactions of the Royal Academy of Medicine in Ireland.* 1885; 3: 439–446.
- [4] Arraez-Aybar LA, Sobrado-Perez J, Merida-Velasco JR. Left musculus sternalis. *Clin Anat.* 2003; 16: 350–354.
- [5] Natsis K, Tollis T. A rare accessory muscle of the anterior thoracic wall. *Clin Anat.* 2007; 20: 980–981.
- [6] O'Neill MN, Folan-Curran J. Case report: bilateral sternalis muscles with a bilateral pectoralis major anomaly. *J Anat.* 1998; 193: 289–292.
- [7] Parsons FG. On the Morphology of the musculus sternalis. *J Anat Physiol.* 1893; 27: 505–507.
- [8] Sarikcioglu L, Demirel BM, Oguz N, Ucar Y. Three sternalis muscles associated with abnormal attachments of the pectoralis major muscle. *Anatomy.* 2008; 2: 67–71.
- [9] Harish K, Gopinath KS. Sternalis muscle: importance in surgery of the breast. *Surg Radiol Anat.* 2003; 25: 311–314.
- [10] Sadler T. *Langman's Medical Embryology.* 11th Ed., Maryland, Lippincott Williams and Wilkins. 2010; 143–149.